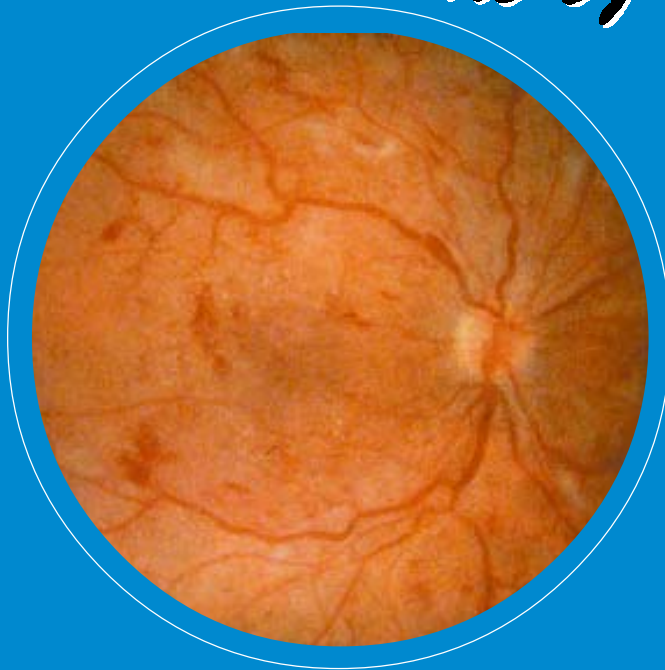


M A N A G I N G

DIABETIC RETINOPATHY

An eye on the eye



<Your Hospital Name>

<Your Logo>

It's difficult living with Diabetes Mellitus. Ask any diabetic...

Their lives are centered around meal plans, glucose levels, and insulin or medication. The heart, kidneys, nerves and eyes could also be affected..... making life miserable.

Are you aware.....

- Diabetics are twice as likely to develop eye problems than nondiabetics. The most common eye complication in diabetes is diabetic retinopathy; the other instances are cataract and glaucoma.
- 50 percent of diabetics develop some degree of diabetic eye disease.
- The risk of blindness is 25 times higher in diabetics.
- Early detection and timely treatment of diabetic eye disease significantly reduces risk of vision loss.
- Diabetic retinopathy is often symptomless in the early stages. Since only an ophthalmologist can detect early signs of diabetic retinopathy, all diabetics should have their eyes examined at least once a year.
- Laser treatment is very successful in treating diabetic retinopathy, if initiated early.

Diabetic Retinopathy: A Silent Presence

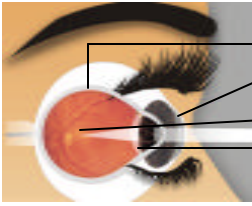
Increasing incidence of diabetes mellitus poses a major health problem in India. The contributing factors are increasingly inappropriate diet high in fat and carbohydrates, sedentary lifestyles and obesity. Regardless of the type of diabetes, many diabetics develop a complication called diabetic retinopathy: a change in the retinal blood vessels that could lead to loss of vision.

Diabetic retinopathy is the foremost cause of blindness in developed countries. In India, it was the 17th cause of blindness 20 years ago, but today the diabetes related blindness had rapidly ascended to the 6th position. Diabetes has been described and aptly so, as a disease of complications. The complications of diabetes are more agonising and torturing than the disease itself.

Diabetic retinopathy is gradual in onset. It is very often symptomless and worsens over time, leading to partial or total visual loss. The onset of diabetic retinopathy is related to the duration of diabetes. The development and progression of diabetic retinopathy is influenced by high blood glucose levels, high blood pressure and genetics and it worsens rapidly when diabetic nephropathy develops. Young diabetic patients have higher risk for developing diabetic retinopathy and greater risk for losing vision. All diabetics need to have their eyes tested regularly. Physicians and ophthalmologist need to work together in controlling diabetic retinopathy. Controlling diabetes, regular eye checkups, treatment/surgery if needed may slow down the development of diabetic retinopathy and prevent significant visual loss.

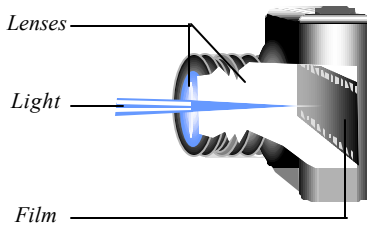
The Normal Eye

The human eye is the smallest; yet the most detailed and complex organ.

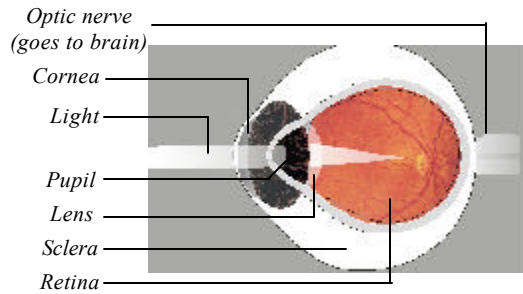


- The vitreous is a clear gel-like substance that fills the back of the eye.*
- The cornea is the “window” that allows light enter the eye.*
- The sensitive tissues of the retina receive light and send it to the brain.*
- The lens helps to focus light after it passes through the cornea.*

The eye works in much the same way as a camera

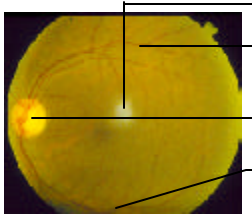


The Camera



The Eye

A Healthy Retina



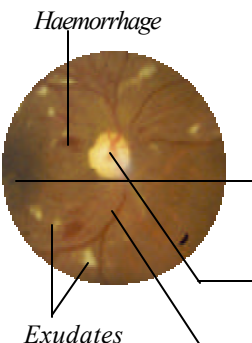
- The macula is responsible for sharp, central vision.*
- The retina is nourished by healthy blood vessels which bring nutrients and oxygen.*
- The optic nerve carries impulses to the brain where they are converted into visual images.*
- The periphery, or outer part of the retina is responsible for peripheral vision.*
- The delicate retinal tissues of the eye convert light into impulses. These impulses are carried to the brain, which converts them into visual images.*

Different parts of the retina such as the periphery, macula, blood vessels and the optic nerve are responsible for different aspects of vision.

Diabetes and the Eye

Diabetic Retinopathy

Diabetes produces weakening of the blood vessels in the body. The tiny delicate retinal blood vessels are particularly susceptible. This deterioration of retinal blood vessels, accompanied by structural changes in the retina is termed as diabetic retinopathy. In diabetic retinopathy, the retina may go through a series of changes like leakage or closure of capillaries. These changes may progress from one to the next.



- The macula may become damaged if blood vessels weaken near the fovea. Central vision will be reduced due to leakage of fluid, exudates or blood in the macula. The impulses sent by the optic nerve may be distorted due to deterioration of blood vessels in the retina.*
- Blood vessels which deteriorate cannot adequately nourish the retina, which in turn will stimulate the growth of new vessels.*

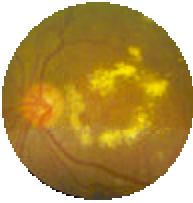Types of Diabetic Retinopathy

There are two main categories of diabetic retinopathy:

Non proliferative diabetic retinopathy (when the blood vessels leak and then close), and proliferative diabetic retinopathy (when new blood vessels grow or proliferate).

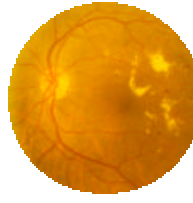Non Proliferative Diabetic Retinopathy (NPDR)

In nonproliferative diabetic retinopathy (also called background retinopathy), the retina may contain capillary leakage, capillary closure, or a combination of the two.



Macular edema

There is swelling and fluid accumulation in the fovea.



Diffuse leakage

Swelling is caused by scattered leakage throughout the macula.

Proliferative Diabetic Retinopathy (PDR)

Progression to proliferative retinopathy is common in long standing diabetes. Besides having non proliferative retinopathy, there may be vessels growing on the retina, and the complications that stem from them.



Proliferative

New vessels which are weaker than normal vessels will replace the vessels that are closed up.



Severe bleeding

New blood vessels rupture and bleed into the retina and the vitreous, with its attendant complications.

Eye Evaluation in Diabetic Retinopathy

Diabetic retinopathy can progress rapidly without much warning. Hence periodic eye examination is the only way to monitor the progression of disease and one can tackle vision threatening problems before or further damage can occur.

1. Recording Patient's History

The onset of diabetic retinopathy is related to the duration of diabetes. Hence the ophthalmologist asks the patient about the duration and family history of diabetes. Any history of eye problems is also looked into.

2. Vision

The goal of the eye examination is to evaluate and improve vision, if possible.

3. Diagnosing Diabetic Retinopathy

Diagnostic tools such as a slit lamps, ultra sound and procedures like fluorescein angiography are used in addition to an ophthalmoscope to assess whether a patient has diabetic retinopathy or other eye problems.

Fluorescein Angiography

This is a magnified photography of the retina involving the use of an injectable dye. It helps to classify the condition and to record changes in the retinal blood vessels. The first angiogram is usually done during the first evaluation. Subsequent angiograms may be done to assess the progression of diabetic retinopathy and to decide on the mode of treatment.

Treatment of Diabetic Retinopathy

Lasers are widely used in treating diabetic retinopathy. It can slow down the progression of diabetic retinopathy and can stabilise vision. Research in developed countries has established that laser is the only treatment for diabetic retinopathy. No medical treatment is available for retinopathy separately other than good blood glucose control.

What is Laser?

Laser is an intense and highly energetic beam of light that emerges from a light source and is focussed on the retina. Absorption by the retina will either seal or destroy the abnormal tissue.

Patterns of Laser Treatment

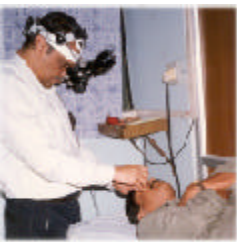Laser treatment reduces swelling by sealing the weak leaking vessels in the retina. It also regresses the new vessels hence prevents or stops bleeding.

Laser treatment in diabetic retinopathy is of three types:

- Focal treatment
- Grid treatment
- Panretinal treatment

The laser experience

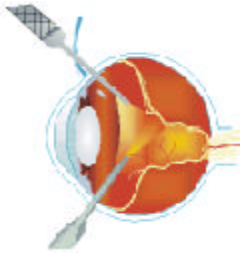
Laser treatment usually takes place in an out-patient setting. The patient is given topical anaesthesia to prevent any discomfort. The patient is positioned before a slit lamp. The ophthalmologist guides the laser beam precisely on the target, with the aid of a slit lamp and a special contact lens. Additional treatment may be required depending on the patient's condition. Lasers can also be delivered through an indirect ophthalmoscope.



Side Effects

Some patients experience side effects after laser treatment. These are usually temporary. Possible side effects include watering of eyes, dilated pupils, mild headache, double vision, pain and mild

blurring of vision. If these side effects persists or worsen one should contact an ophthalmologists immediately.



Vitrectomy

In some patients, there may be bleeding into the vitreous or the vitreous may pull on the retina reducing vision severely. In such instances a vitrectomy (removal of the vitreous) is the choice of treatment. A vitrectomy is done only after other forms of treatment have been tried and failed to control the progression of disease or progression of visual loss.

The importance of regular eye care

Screening guidelines for detailed medical eye examination for persons with diabetes

Table-1

Age of onset of diabetes mellitus	Recommended time of first eye examination	Routine minimum follow-up
0-30 years	Within 5 years of diagnosis	Yearly
31 years and above	Upon diagnosis	Yearly
During Pregnancy	Early in the first trimester	3 months

Table - 2

Observed Retinal Abnormality	Follow-up
None or rare microaneurysms (5% to 10% one-year incidence of developing retinopathy)	Yearly
Mild non proliferative diabetic retinopathy (12% four-year incidence of developing macular edema)	Every 9 Months
Moderate NPDR (23% four-year incidence of developing macular edema)	Every 6 Months
Severe NPDR (10% to 50% one-year incidence of developing Non proliferative diabetic retinopathy).	Every 4 Months
Diabetic Retinopathy with clinically significant Macular Edema occurring at any level of retinopathy	Every 2-4 Months* (careful Follow-up)
Proliferative diabetic retinopathy (PDR)	Every 2-3 Months* (careful Follow-Up)

Diabetic Retinopathy is symptomless until the last stage. Once the symptoms show up, it is often too late to prevent visual loss. Hence all diabetics must visit the ophthalmologist once in a year to monitor the retina and watch for diabetic retinopathy. Once it is diagnosed, they may need more frequent visits to check the progress of the disease and get treated.

All diabetics should have a periodic eye examination by an ophthalmologist familiar with treatment of diabetic eye disease.

This booklet contains information about your role as a physician in preventing blindness in your diabetic patients. You are the first point of contact for your diabetic patients. You see them often . . . they trust you, count on your advice and support . . . and look up to enable them cope with the disease. This is where you , dear doctor, can make all the difference to your patient. Being at the right place and right time obviously makes you the right person to make a positive impact on them - their eyes and in the quality of their lives

You can help by

- educating your diabetic patients about their increased risk of visual loss because of the disease
- explaining to your patients the need for regular eye checkups by an ophthalmologist
- counselling your patients about the importance of early detection and timely treatment in protecting their vision



You owe it to your patients

Together we can make their world a better place...