

Review Article

Ophthalmic regional anaesthesia: A review and update

Address for correspondence:

Dr. VV Jaichandran,
Department of
Anaesthesiology, Sankara
Nethralaya, 41/18, College
Road, Nungambakkam,
Chennai, Tamil Nadu, India.
E-mail:
jaichand1971@yahoo.com

VV Jaichandran

Department of Anaesthesiology, Medical Research Foundation, Sankara Nethralaya, 41/18, College Road, Nungambakkam, Chennai, Tamil Nadu, India

ABSTRACT

Local anaesthetic techniques are increasingly popular for ophthalmic surgery. It is now being provided mainly by anaesthesiologists and varies from an akinetic injection technique to a non-akinetic topical technique. Each technique has its own risk/benefit profile, and proven to be highly successful if performed correctly. The choice of the technique should be individualized based upon specific needs of the patient, the nature and extent of eye surgery, and the anaesthesiologist's and surgeon's preferences and skill. This review article attempts to outline the orbital anatomy, discuss the commonly used agents, current method of pre-operative preparation, available clinical techniques and their inherent complications.

Key words: Peribulbar, regional ophthalmic anaesthesia, retrobulbar, sub-Tenon's

Access this article online

Website: www.ijaweb.org

DOI: 10.4103/0019-5049.108552

Quick response code



INTRODUCTION

Eye surgeries had been performed with little or no anaesthesia for almost a 1000 years. The "Year 1884" was a watershed year for ophthalmic anaesthesia; it was in this year that Carl Koller discovered cocaine hydrochloride as a topical anaesthetic agent for performing eye surgery and Herman Knapp used cocaine for retrobulbar injection and performed enucleation. Various local anesthetic techniques have evolved since then including both akinetic (needle/cannula-based technique)^[1,2] and non-akinetic (topical anaesthesia) techniques.^[3] The advent of clear corneal phacoemulsification combined with foldable intraocular lens brought a resurgence to the non-akinetic technique as a safe and easy form of ocular anaesthesia.

It should, however, be taken into account that topical anaesthesia does have its own limitations. As a process, it lays a high emphasis on patient co-operation in addition to the surgeon's skills on the table; studies also indicate that patients have a preference to the akinetic technique.^[4] It should be relevant to note here that ophthalmic anaesthesiologists are increasingly

involved in performing regional orbital blocks which were performed only by surgeons in the past.

This review on ophthalmic anaesthesia assumes high importance in the light of the fact that it outlines orbital anatomy, current methods of pre-operative preparation, need for ophthalmic evaluation, available clinical techniques and their inherent complications.

RELEVANT ANATOMY

Orbit

The orbit is an irregular four-sided pyramid. The medial wall of each orbit lies parallel to the contralateral medial orbital wall. The lateral wall of each orbit forms a 90° angle with the contralateral lateral orbital wall. The medial wall is separated from the ethmoid sinus by a very thin portion of the ethmoidal bone called the lamina papyracea. Perforation of the medial wall by a needle may result in orbital cellulitis or abscess.

Globe

The globe is situated in the anterior part of the orbital cavity closer to the roof than the floor and nearer

How to cite this article: Jaichandran VV. Ophthalmic regional anaesthesia: A review and update. *Indian J Anaesth* 2013;57:7-13.

the lateral wall than the medial wall. Axial length of 26 mm or more denotes a myopic eye and they carry risk of one perforation for every 140 needle blocks performed.^[5]

Extraocular muscles

Globe movements are controlled by the rectus muscles (inferior, lateral, medial and superior) and the oblique muscles (superior and inferior). The rectus muscles arise from the annulus of Zinn near the apex of the orbit and insert anterior to the equator of the globe, forming an incomplete cone.

Nerve supply

Within the muscle cone lie the optic nerve (II), oculomotor nerve (III), abducens nerve (VI nerve), nasociliary nerve (a branch of V nerve), ciliary ganglion and blood vessels. The oculomotor nerve supplies the levator palpebrae muscle, inferior oblique, superior, inferior and medial rectus. The abducens nerve supplies the lateral rectus. The trochlear nerve (IV nerve) supplies the superior oblique muscle. This muscle is frequently not paralyzed as anaesthetic agents often fail to block IV nerve, which lie outside the muscle cone. Corneal and perilimbal conjunctival and superonasal quadrant of the peripheral conjunctival sensations are mediated through the nasociliary nerve. The remainder of the peripheral conjunctival sensation is supplied through the lacrimal, frontal and infraorbital nerves coursing outside the muscle cone.

Pre-operative ophthalmic evaluation

Elements of ophthalmic evaluation which are important to the anaesthesiologists include history of previous ophthalmic surgery, glaucoma, knowledge about the axial length, presence of any staphyloma, and the relationship between globe and orbit. Buckling surgery alters globe dimensions, contour and results in significant scarring within the orbit and so increases the potential of perforation.^[6] The axial length and the presence and location of staphyloma can be known from B-scan echography, which is usually done, before cataract surgery, for diopter power calculation.

Orbital: Globe spatial relationship

The orbital axis (OX) is the bisection of line between medial and lateral orbital walls, while visual axis (VX) is the position of the eye in primary gaze. Both the axis diverge at an angle of 23° [Figure 1]. Normally, the equator of the globe is at or slightly anterior to the lateral orbital rim and the spatial relationship between them is assessed by measuring the distance the

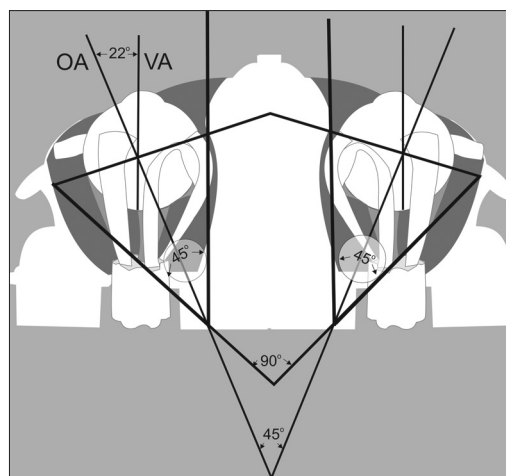


Figure 1: Relationship between the orbit and globe. OA – Orbital axis; VA – Visual axis

globe (top of the cornea) extends over the infraorbital rim and this distance is generally about 8 mm.^[7]

Forward set globe

The globe extends quite forwardly over the infraorbital rim (>8 mm) and associated eyelids will be lax with wide palpebral fissure and high brows. Here, the structures in the apex of the orbit are vulnerable to get injured with needle blocks.

Deep set globe

In this condition, there is high chance for the needle to come in contact with the globe. Associated eyelids will be short and tight. From the point of insertion, at the inferolateral quadrant, the needle must not be angulated more than 10° elevation from the transverse plane.

PRE-OPERATIVE SYSTEMIC ASSESSMENT AND PREPARATION

Detailed history and physical examination should be carried out for every patient. Certain basic investigations such as blood sugar estimation and ECG especially in patients aged 60 years and above can be carried out as a routine and to let clinical judgment guide the need for more extensive investigations.^[8] Pre-operative optimisation of medical conditions (control of blood sugar, blood pressure, etc.) is required before they could be taken up for planned surgery. Antiplatelet or anticoagulant can be continued for patients posted for cataract surgery (least risk for haemorrhage). Patients on anticoagulant should have international normalized ratio (INR) measured, close to the time of surgery, ideally on the same day and INR should be within

the recommended therapeutic range. For non-cataract ocular and orbital surgery (intermediate to high risk of haemorrhage), there should be discussions among the anaesthesiologist, surgeon and patient regarding the risks and benefits of continuing/discontinuing anticoagulant and antiplatelet drugs and to agree to an acceptable approach such as bridging therapy in the interest of total patient care.^[9,10]

ECG, blood pressure and pulse oximeter are connected. An intravenous line must be inserted before embarking on a needle block. Patients should receive oxygen 2 L/min via nasal catheters placed near the patient's nostrils.^[11]

AKINETIC TECHNIQUES

Needle based technique

Modern retrobulbar block

In the modern retrobulbar block, 23 G, 31 mm long needle, with bevel facing the globe, is inserted through the skin in the inferotemporal quadrant as far laterally as possible, just above the junction of inferior and lateral orbital walls [Figure 2].^[12,13] The Atkinson's or classic insertion site, i.e., the junction of medial two-third and lateral one-third of the lower orbital margin, is no more recommended. The reasons cited are the needle being nearer to the globe, inferior rectus muscle, and also closer to the neurovascular bundle supplying the inferior oblique. Several cases of diplopia owing to iatrogenic needle injury to inferior rectus and oblique muscles following needle entering at this site have been reported in the literature.^[14,15]

From the extreme corner, it is easier to stay far away from the globe and would prevent any needle injury to the

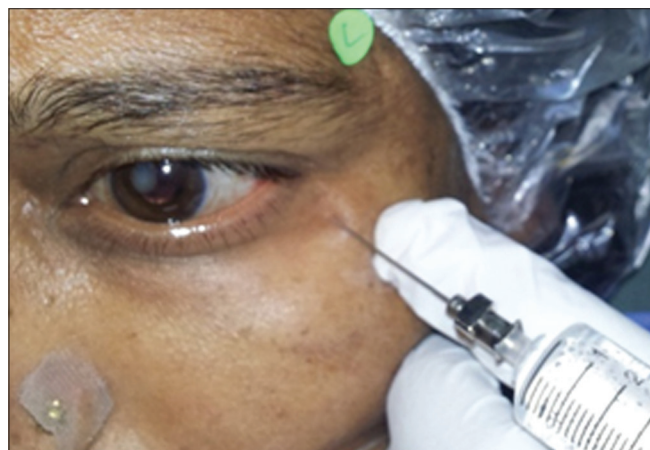

Figure 2: Needle entry site at the extreme inferotemporal corner for performing regional eye block

inferior rectus muscle or its neurovascular bundle. The initial direction of the needle is tangential to the globe. Once past the equator, as gauged by the axial length of the globe, the needle is allowed to go upwards and inwards.^[16] With the eye in primary gaze, 4 to 5 cc of local anaesthetic agent is injected. All extraocular muscles can be paralyzed by this technique except superior oblique. The entire globe is anaesthetized as a result of blocking the nasociliary and the long ciliary nerves. Akinesia of the eyelids may be incomplete. A separate eyelid block, using 2.5 cc of 1% lignocaine solution injected 0.5 cm below (lower lid) and 1.0 cm above (upper lid) the middle of the canthus, might be required.^[17]

Modern peribulbar block

A 23-G, 25 mm long needle is inserted as far laterally as possible in the inferotemporal quadrant. Once the needle is under the globe, it is directed along the orbital floor, passing the globe equator to a depth controlled by observing the needle/hub junction reaching the plane of the iris.^[18] After negative aspiration for blood, with the globe in primary gaze, 4 to 5 cc of local anaesthetic agent is injected.

By this procedure, all extraocular muscles including superior oblique can be paralyzed. The local anaesthetic solution diffuses through the orbital septum and orbicularis muscle can also be paralyzed. A separate eyelid block might not be required with this technique.

Following a fractionated inferotemporal injection, intraocular pressure increases significantly and this may lead to vitreous loss during intraocular surgery.^[19] Hence adequate compression of the globe either by using digits or Honan Intraocular pressure reducer should be done. The ocular digital compression is done gently with the middle three fingers placed over a sterile gauze pad on the upper eyelid with the middle finger pressing directly down on the eyeball. For every 30 s, digital pressure is released for 5 s to allow for the vascular pulsations to occur (intermittent digital pressure).^[20] The ocular compression device most commonly used is Honan's balloon which is applied for 10-20 min with the pressure set at 30 mmHg. After adequate compression, if significant movement of the eye still persists then supplementary injection, medial peribulbar block is administered. The administration of this supplementary injection depends on the type and duration of the procedure to be performed, the experience of the ophthalmologist, and preference of the anaesthesiologist.

Medial peribulbar block is given using 26 G, ½' disposable needle. With the bevel facing the medial orbital wall, needle is passed into the blind pit, between the medial caruncle and canthus [Figure 3]. It is passed backwards in the transverse plane, directed at 5° angle away from the sagittal plane and towards the medial orbital wall. If the medial wall is contacted, the tip is slightly withdrawn and needle is redirected to a depth of 15-20 mm and after negative aspiration for blood, 3-5 cc of local anaesthetic solution is injected.^[16] This extraconal space is an excellent site for administering local anaesthesia, as it communicates freely with the intraconal space. Also, with this injection, eyelids may fill with the anaesthetic solution which provides excellent orbicularis akinesia too.

Injection at superomedial quadrant should not be administered. Superomedial quadrant is more vascular in nature when compared to the remaining other three quadrants resulting in more chances of haemorrhage to occur in the lid and as the globe is closer to the roof than to the floor, superomedial block *per se* can result in perforation of the globe.^[21]

Complications of needle blocks

Systemic complications

Toxicity (arising because of overdose or intravascular injection) and vasovagal reactions are the most common systemic complications associated with local anaesthesia. Hyaluronidase, an additive used to promote the onset and quality of the block, may rarely cause allergic reactions.^[22]

Brainstem anaesthesia

Inadvertent intra-arterial injection of the anaesthetic

agent can result in retrograde flow of the agent from the ophthalmic artery to the cerebral or internal carotid artery resulting in CNS spread of anaesthesia. Also, the anaesthetic can be inadvertently injected under the dura matter sheath of the optic nerve resulting in subarachnoid spread of the local anaesthetic. There is a continuum of sequelae, depending on the amount of drug that gains access to the CNS and the specific area to which the drug spreads. The signs and symptoms may include violent shivering, contralateral amaurosis, loss of consciousness, apnea, hemiplegia, paraplegia or quadriplegia.^[23,24] Blockade of the eighth to twelfth cranial nerves will result in deafness, tinnitus, vertigo, dysarthria, dysphagia, and aphasia.^[25,26] These signs may present themselves in various combinations and the anaesthesiologist must be alert and prepared to provide cardiopulmonary resuscitation as an emergency, when there are apparent signs of local anaesthesia spreading to the CNS. While symptomatic and proper treatment can lead to total recovery of the patient, delay in diagnosing and treating could be fatal.

Orbital complications

Retrobulbar haemorrhage

It is caused by needle penetration of either the venous or arterial vessels in the orbit. Venous haemorrhage is slow in onset, presents as markedly blood stained chemosis and does not ordinarily threaten vision.^[27] Intermittent digital pressure with a gauze pad over the closed lids is required to reduce the raised IOP, if it occurs. Arterial haemorrhages, however, can be more serious. Immediate symptoms include proptosis, tight eyelids, ecchymosis, lid swelling and a dramatic increase in intraocular pressure.^[13,27] Firm digital pressure usually stops the bleeding. A compressive retrobulbar haemotoma may threaten retinal perfusion by causing central retinal artery occlusion.^[27] Most retrobulbar haemorrhage can be successfully treated conservatively.^[13] The ophthalmologist will evaluate the extent of the haemorrhage and determine whether further interventions are necessary. IOP can be lowered with acetazolamide or intravenous mannitol.^[13] Rarely, immediate lateral canthotomy or even paracentesis might be required to relieve orbital pressure.^[27]

Globe damage

While globe perforation refers to double puncture wounds (entry and exit wound), globe penetration has only a wound of entry. Patients with an axial length of >26 mm are prone to globe perforation.^[13,28] Other risk factors include deep set eye, repeated

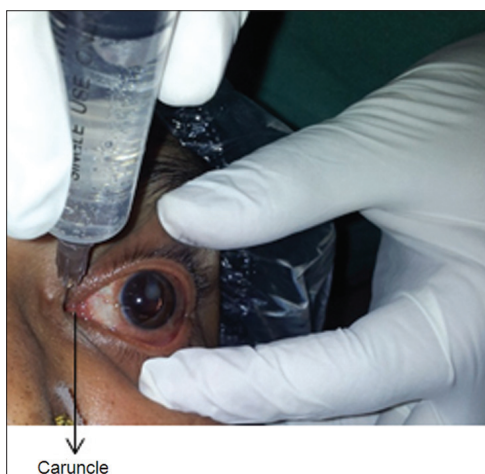

Figure 3: Needle entering between caruncle and medial canthal angle for performing medial peribulbar injection

injections and previous sclera buckling.^[18,29,30] Signs and symptoms of perforation include intense ocular pain, sudden loss of vision and hypotonus.^[30] Retinal surgeon's opinion should be strongly considered.

Optic nerve damage

The tip of the needle may pierce the optic nerve, causing direct damage, leading to optic atrophy. The risk factors for optic nerve damage include patients looking up and in during the classical retrobulbar block, those with small orbits and long needle aiming at the orbital apex.^[31]

Myotoxicity

Possible mechanisms of extraocular muscle damage include direct needle trauma, ischemic pressure necrosis caused by large volume of local anaesthetic and direct myotoxic effects of the local anaesthetic agent on extraocular muscles.^[13,32]

CANNULA BASED INJECTION TECHNIQUE

Sub-Tenon's block

It was introduced into clinical practice in the early 1990s as a simple, safe, effective and versatile alternative to needle block.^[2,33] It is also known as parabolbar, pinpoint anaesthesia^[34] or episcleral block.^[35] Local anaesthetic eye drops are instilled onto the conjunctiva. Under sterile conditions, at the inferonasal quadrant, 3-5 mm away from the limbus, the conjunctiva and Tenon capsule are gripped with non-toothed forceps and a small incision is made through these layers with Westcott scissors to expose the sclera. A blunt curved posterior sub-Tenon's cannula mounted on to a 5 mL syringe with local anaesthetic is inserted through the hole along the curvature of the sclera. Injection of local anaesthetic agent under the Tenon capsule blocks the sensation from the eye by action on the short ciliary nerves as they pass through the Tenon capsule to the globe. Akinesia is obtained by direct blockade of anterior motor nerve fibres as they enter the extraocular muscles. Akinesia is variable and volume dependent. 2% lidocaine is the most commonly used local anaesthetic agent.^[36]

Although it was reported to be safe compared to needle blocks, complications such as orbital and retrobulbar haemorrhage, globe perforation, the central spread of local anaesthetic, orbital cellulitis, etc., have been reported in the literature.^[37-39] The other minor complications known to occur are chemosis and conjunctival haemorrhage.^[16]

Pharmacological considerations

Local anaesthetic agents

2% lignocaine provides a rapid onset of dense sensory and motor blockade and duration of action is usually sufficient for performing cataract surgery. On the other hand, 0.5% bupivacaine provides longer duration of action providing the patient and the anaesthetist with a buffer of comfort for longer procedures such as vitreo-retinal cases. A mixture of lignocaine and bupivacaine is the most popular preparation used for ophthalmic blocks.^[40] Ropivacaine and levobupivacaine are some of the newly marketed amide group of local anesthetic agents that have been found to be useful for eye surgery.^[41,42]

Adjuvants

Hyaluronidase

It is an enzyme that reversibly liquefies the interstitial barrier between cells by depolymerisation of hyaluronic acid to a tetrasaccharide, thereby enhancing the diffusion of molecules through tissue planes. It has been shown to improve the onset and enhance the quality of retrobulbar, peribulbar and sub-Tenon's block.^[43,44] Although varying amount of hyaluronidase (5-150 IU/mL) have been used by authors, it is better to limit the concentration to 15 IU/mL.^[16]

pH value

Local anaesthetics are weak bases. At higher pH values, a greater proportion of local anaesthetic molecules exist in the non-ionized form, allowing more rapid influx into the neuronal cells. Also, the nociceptor receptors are also less sensitive to the non-ionized form of the drug.^[45] Thus, alkalinisation has a proven impact in decreasing onset time, prolonging the duration of action and also decreasing the pain experienced by the patient during injection of the local anaesthetic.^[46]

NON-AKINETIC TECHNIQUE

Topical anaesthesia

It can be achieved either by instilling local anaesthetic eye drops (0.5% proparacaine hydrochloride or 2-4% lignocaine)^[47] or application of lignocaine gel^[48] and is found to be useful for cataract, glaucoma surgery like trabeculectomy^[49] and secondary intraocular lens implantation. Topical anaesthetic agents block trigeminal nerve endings in the cornea and conjunctiva, leaving the intraocular structures in the anterior segment unanaesthetized. Thus, manipulation of the iris and stretching of the ciliary and zonular tissues during surgery can irritate the ciliary nerves,

resulting in discomfort. A modified technique consists of combining topical anaesthesia with 0.5 mL of 1% lignocaine (preservative free) injected through the side port incision after evacuation of aqueous (intracameral anaesthesia).^[50] It provides sensory blockage of the iris and ciliary body and thereby relieves discomfort experienced during intraocular lens placement.

Retained visual sensations that include seeing light, colours, movements and instruments during surgery are expected to occur more frequently under topical anaesthesia because optic nerve function is not affected. Although the majority of patients feel comfortable with visual sensations they experience, a small proportion finds the experience unpleasant or frightening.^[51] Pre-operative counseling and IV midazolam are known to alleviate the fear caused by intra-operative visual images seen.^[52]

SUMMARY

Although there are various techniques available to achieve anaesthesia of the globe, each technique has its own advantages and disadvantages. The choice of the technique should be individualized based on specific needs of the patient, the nature and extent of eye surgery, and the anaesthesiologist's and surgeon's preferences and skills. However, a thorough knowledge of the orbital anatomy and training are imperative for practicing safe orbital regional anaesthesia.

ACKNOWLEDGMENT

The author would like to thank Dr. Mohan and Mr. Biswarup Mukerjee, Department of Electrical Engineering, Indian Institute of Technology, Madras, for helping us to reproduce the diagrams.

REFERENCES

1. Davis DB II, Mandel MR: Posterior peribulbar anesthesia: An alternative to retrobulbar anesthesia. *J Cataract Refract Surg* 1986;12:182-4
2. Hansen EA, Mein CE, Mazzoli R. Ocular anesthesia for cataract surgery: A direct sub-Tenon's approach. *Ophthalmic Surg* 1990;21:696-9.
3. Assia EI, Pras E, Yehezkel M, Rotenstreich Y, Jager-Roshu S. Topical anesthesia using lidocaine gel for cataract surgery. *J Cataract Refract Surg* 1999;25:635-9.
4. Friedman DS, Reeves SW, Bass EB, Lubomski LH, Fleisher LA, Schein OD. Patient preferences for anaesthesia management during cataract surgery. *Br J Ophthalmol* 2004;88:333-5.
5. Rinkoff GS, Doft BH, Lobes LA. Management of ocular penetration from injection of local anesthesia preceding cataract surgery. *Arch Ophthalmol* 1991;109:1421-5.
6. Duker JS, Belmont JB, Benson WE, Brooks HL Jr, Brown GC, Federman JL, *et al.* Inadvertent globe perforation during

- retrobulbar and peribulbar anesthesia. *Ophthalmology* 1991;98:519-26.
7. Wolff E. *Anatomy of the Eye and Orbit*. Philadelphia and London: WB Saunders; 1966. p. 31.
8. Local anaesthesia for ophthalmic surgery. Joint Guidelines of The Royal college of Anaesthetists and the Royal college of Ophthalmologists [Last accessed on 2012 Nov 20].
9. Mather SJ, Kong KL, Vohra SB. Loco-regional anaesthesia for ocular surgery. Anticoagulant and antiplatelet drugs. *Curr Anaesth Crit Care* 2010;21:158-63.
10. Katz J, Feldman MA, Bass EB, Lubomski LH, Tielsch JM, Petty BG, *et al.* Study of medical testing for cataract surgery team. Risks and benefits of anticoagulants and antiplatelet medication use before cataract surgery. *Ophthalmology* 2003;110:1784-8.
11. Risdall JE, Geraghty IF. Oxygenation of patients undergoing ophthalmic surgery under local anaesthesia. *Anaesthesia* 1997;52:492-5.
12. Fanning GL. Orbital regional anesthesia- ocular anaesthesia. *Ophthalmol Clin North Am* 2006;19:221-32.
13. Kumar CM, Dowd TC. Complications of ophthalmic regional blocks: Their treatment and prevention. *Ophthalmologica* 2006;220:73-82.
14. Gomez-Arnau JI, Yanguela J, Gonzalez A, Andres Y, Garcia del Valle S, Gili P. Anaesthesia-related diplopia after cataract surgery. *Br J Anaesth* 2003;90:189-93.
15. Taylor G, Devys JM, Heran F, Plaud B. Early exploration of diplopia with magnetic resonance imaging after peribulbar anaesthesia. *Br J Anaesth* 2004;92:899-901.
16. Kumar CM, Dodds C. Ophthalmic Regional blocks: Review article. *Ann Acad Med Singapore* 2006;35:158-67.
17. Schimek F, Fahle M. Techniques of facial nerve block. *Br J Ophthalmol* 1995;79:166-73.
18. Hamilton RC. Techniques of orbital regional anaesthesia. *Br J Anaesth* 1995;75:88-92.
19. Venkatakrishnan J, Vijaya L, George RJ, Thennarasu M. Effect of varying duration of ocular compression on raised intraocular pressure following fractionated peribulbar anesthesia for cataract surgery. *Asian J Ophthalmol* 2011;12:197-200.
20. Levin ML, O'Connor PS. Visual acuity after retrobulbar anesthesia. *Ann Ophthalmol* 1989;11:337-9.
21. Gadkari SS. Evaluation of 19 cases of inadvertent globe perforations due to periocular injections. *Indian J Ophthalmol* 2007;55:103-7.
22. Ahluwalia HS, Lukaris A, Lane CM. Delayed allergic reaction to hyaluronidase: A rare sequel to cataract surgery. *Eye (Lond)* 2003;17:263-6.
23. Lee DS, Kwon NJ. Shivering following retrobulbar block. *Can J Anaesth* 1988;35 (Pt 1):294-6.
24. Gomez RS, Andrade LO, Costa JR. Brainstem anaesthesia after peribulbar anaesthesia. *Can J Anaesth* 1997;44:732-4.
25. George RB, Hackett J. Bilateral hearing loss following a retrobulbar block. *Can J Anaesth* 2005;52:1054-7.
26. Rosen WJ. Brainstem anesthesia presenting as dysarthria. *J Cataract Refract Surg* 1999;25:1170-1.
27. Cyriac IC, Pineda R. Postoperative complications of periocular anesthesia. *Int Ophthalmol Clin* 2000;40:85-91.
28. Kallio H, Rosenberg PH. Advances in ophthalmic regional anesthesia. *Best Pract Res Clin Anaesthesiol* 2005;19:215-27.
29. Troll GF. Regional ophthalmic anesthesia: Safe technique and avoidance of complications. *J Clin Anesth* 1995;7:163-72.
30. Kumar CM. Orbital regional anesthesia: Complications and their prevention. *Indian J Ophthalmol* 2006;54:77-84.
31. Hamilton RC. A discourse on the complications of retrobulbar and peribulbar blockade. *Can J Ophthalmol* 2000;35:363-72.
32. Wong DH. Review article. Regional anaesthesia for intraocular surgery. *Can J Anaesth* 1993;40:635-57.
33. Stevens JD. A new local anaesthesia technique for cataract extraction by one quadrant sub-Tenon's infiltration. *Br J Ophthalmol* 1992;76:670-4.

34. Fukasaku H, Marron JA. Sub-Tenon's pinpoint anesthesia. *J Cataract Refract Surg* 1994;20:673.
35. Ripart J, Metge L, Prat-pradal D, Lopez FM, Eledjam JJ. Medial canthus single-injection episcleral (sub-tenon anesthesia): Computed tomography imaging. *Anesth Analg* 1998;87:42-5.
36. Mclure HA, Rubin AP. Review of local anaesthetic agents. *Minerva Anesthesiol* 2005;71:59-74.
37. Rahman I, Ataullah S. Retrobulbar hemorrhage after sub-Tenon's anesthesia. *J Cataract Refract Surg* 2004;30:2636-7.
38. Ruschen H, Bremner FD, Carr C. Complications after sub-Tenon's eye block. *Anesth Analg* 2003;96:273-7.
39. Lip PL. Postoperative infection and subtenon anaesthesia. *Eye (Lond)* 2004;18:229.
40. Hamilton RC, Gimbel HV, Strunin L. Regional anaesthesia for 12,000 cataract extraction and intraocular lens implantation procedures. *Can J Anaesth* 1988;35:615-23.
41. Borazan M, Karalezli A, Akova YA, Algan C, Oto S. Comparative clinical trial of topical anaesthetic agents for cataract surgery with phacoemulsification: Lidocaine 2% drops, levobupivacaine 0.75% drops, and ropivacaine 1% drops. *Eye (Lond)* 2008;22:425-9.
42. Aksu R, Bicer C, Ozkiris A, Akin A, Bayram A, Boyaci A. Comparison of 0.5% levobupivacaine, 0.5% bupivacaine, and 2% lidocaine for retrobulbar anesthesia in vitreoretinal surgery. *Eur J Ophthalmol* 2009;19:280-4.
43. Crawford M, Kerr WJ. The effect of hyaluronidase on peribulbar block. *Anaesthesia* 1994;49:907-8.
44. Guise P, Laurent S. Sub-Tenon's block: The effect of hyaluronidase on speed of onset and block quality. *Anaesth Intensive Care* 1999;27:179-81.
45. Mackay W, Morris R, Mushlin P. Sodium bicarbonate attenuates pain on skin infiltration with lidocaine, with or without epinephrine. *Anesth Analg* 1987;66:572-4.
46. Jaichandran VV, Vijaya L, George RJ, Bhanulakshmi IM. Peribulbar anesthesia for cataract surgery: Effect of lidocaine warming and alkalization on injection pain, motor and sensory nerve blockade. *Indian J Ophthalmol* 2010;58:105-8.
47. Martini E, Cavallini GM, Campi L, Lugli N, Neri G, Molinari P. Lidocaine versus ropivacaine for topical anaesthesia in cataract surgery. *J Cataract Refract Surg* 2002;28:1018-22.
48. Koch PS. Efficacy of 2% lidocaine jelly as a topical agent in cataract surgery. *J Cataract Refract Surg* 1999;25:632-4.
49. Zabriskie NA, Ahmed II, Crandell AS, Daines B, Burns TA, Patel BC. A comparison of topical and retrobulbar anesthesia for trabeculectomy. *J Glaucoma* 2002;11:306-14.
50. Martin RG, Miller JD, Cox CC, Ferrel SC, Raanan MG. Safety and efficacy of intracameral injections of unpreserved lidocaine to reduce intraocular sensations. *J Cataract Refract Surg* 1998;24:961-3.
51. Tan CS, Au Eong KG, Kumar CM, Rengaraj V, Radhakrishnan M. Fear from visual experiences during cataract surgery. *Ophthalmologica* 2005;19:416; author reply 417.
52. Venkatakrishnan JV, Kumar CM, Ratra V, Viswanathan J, Jeyaraman VA, Ragavendera T. Effect of sedation on visual sensations in patients undergoing cataract surgery under topical anaesthesia: A prospective randomized masked trial. *Acta Ophthalmologica*. [Epub ahead of print] [Last accessed on 2012 Nov 8].

Source of Support: Nil, Conflict of Interest: None declared

Announcement

CALENDAR OF EVENTS OF ISA - 2013

Certain important dates are given here for the members. All the applications should be sent by Regd Post with Ack Due. Online facility is available but supportive documents should be sent

Date	Name of the Award/Post	Application has to be sent to
30 th June 2013	Bhopal Award for Academic Excellence	Hony. Secretary, ISA
31 st July 2013	KPR Young Anaesthesiologist Award State Chapter	Secretary, Kerala State
15 th August 2013	Prof. A. P. Singhal Life Time Achievement Award	Hony. Secretary, ISA
31 st October 2013	Dr (Mrs.) Rukmini Pandit Award - Publication format along with Conference Presentation Certificater	Hony. Secretary, ISA
31 st October 2013	Y. G. Bhoj Raj Award - Best Review Article in IJA	Hony. Secretary, ISA
31 st October 2013	Dr. Kop's Award	Chairman Scientific committee of ISACON with a copy to Hony Secretary ISA
27 th November 2013	Dr. TN Jha Memorial & Dr. KP Chansoriya Travel grant	Hony. Secretary, ISA
27 th November 2013	Late Dr. Venkata Rao Memorial Oration	Hony. Secretary, ISA
27 th November 2013	Ish Narani Best Poster Award	Chairman Scientific Committee ISACON
28 th November 2013	ISA GOLDCON QUIZ Competition	Chairman Scientific Committee ISACON
28 th November 2013	Awards for	Hony. Secretary, ISA
	1. Best City Branch	
	2. Best State Branch	
	3. Best Metro Branch	
	4. Best City Branch	
	5. Public Awareness Individual	
	6. Public Awareness City	
	7. Public Awareness State	
	8. Ether Day / City / State	
	9. Individual Drive	
	10. Highest Membership Drive	

Dr. M V Bhimeshwar
 Hon. Secretary - ISA,
 Mobile – 098480 40868 Phone - 040 - 27178858
 Email: isanhq@isaweb.in
 Website: www.isaweb.in