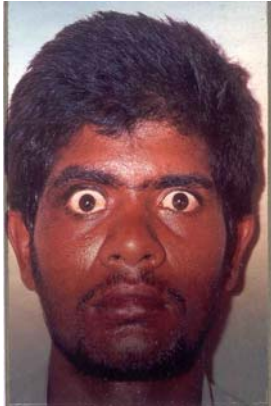
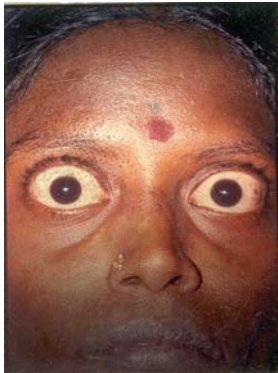

# Thyroid Related Orbitopathy

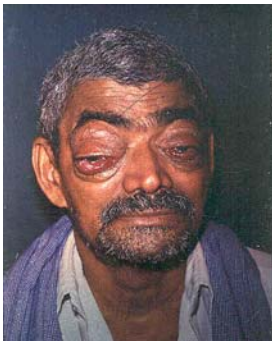

Optic Nerve involvement

Proptosis



Eye Lid elevation



Swelling of tissues