

Clinical Practice Module

Quality
Assurance

in

MANAGEMENT OF PRIMARY OPEN ANGLE GLAUCOMA

Dr. S.R. Krishnadas

Prepared by



Aravind Eye Hospitals

Madurai, Tirunelveli and Coimbatore

For

National Programme for Control of Blindness

Directorate General of Health Services

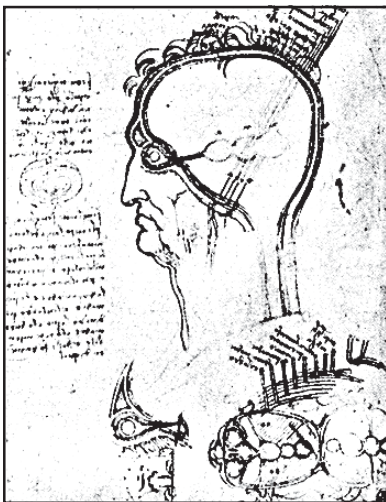Ministry of Health & Family Welfare, Government of India

New Delhi

THE SCIENTIST & OPHTHALMOLOGY

Leonardo da Vinci 1452-1519

Leonardo comprehended the dual nature of the visual process, namely the neurological and the interpretive functions. This is evidenced by his drawings depicting the eye-optic nerve-brain relationship (figure 2), and in his writings. He studied ocular anatomy by dissection and arrived at conclusions that were largely intraocular structures. Leonardo's notebooks indicate that he seemed at the threshold of understanding stereopsis and orientation in space when he recognized that having two eyes allows us to see in a "relief and vividness" unattainable by painters working on a canvas. He compared the eye to a camera



obscura but did not accept the idea of the inversion as the final state of the ocular image. He presumed that the image was reinverted by the lens before being perceived. He understood that the "visual faculty" resides "at the extremity of the optic nerve" (retina) and not in the lens, as had been believed since Galen.

Leonardo was close to understanding central macular vision when he wrote: "The pupil barely recognizes the thing that imprints itself far from the center of the opening".

If the paths of philosophical, scientific, technological, and artistic endeavors ever crossed in one personality, it was in this man - a giant of the Renaissance.

All of the diverse talents of this man came together in the field of ophthalmology, in which he made both anatomical and philosophical observations.

Primary Open Angle Glaucoma

Definition

Primary open angle glaucoma (POAG) is an ocular disorder characterised by slowly progressive optic neuropathy with atrophy and cupping of the optic nerve head and associated with characteristic Nerve fiber bundle type of visual field defects and a normal, open iridocorneal angles on gonioscopic evaluation of the anterior chamber. Intraocular pressure(IOP) is an important risk factor for POAG and factors such as age, race and a positive family history contribute to enhanced risk of developing the disease. In addition, reduction in perfusion of the optic nerve head, abnormalities of the axonal or ganglion cell metabolism or disorders of the extracellular matrix of the lamina cribrosa of the optic nerve could be contributory factors in the pathogenesis of the optic nerve damage and visual field loss.

Most patients have a pretreatment IOP exceeding 21 mm Hg when measured with a Goldmann applanation or an equivalent tonometer at some point in the course of their disease. Approximately one-sixth of patients with optic disc and visual field changes characteristic of POAG will have an IOP consistently below 21mmHg¹. These individuals comprise a subset referred to as the Normal Pressure Glaucoma.

POAG: Epidemiology and Magnitude; Risk factors

Several population based studies have been conducted in the west, which have identified POAG as a major health problem. These studies have identified the Black race and an increasing age as principal risk factors for POAG, apart from an elevated IOP. The prevalence of elevated IOP rises from approximately 2% in those younger than 40 to 9% in individuals aged over 70. The prevalence of POAG increases more steeply with age: from 0.1% in the 40-49 age group to 2 to 3% in those aged 70. The risk of glaucomatous damage increases substantially with age and the level of IOP. The proportion of those with elevated IOP who have optic disc and visual field changes, also increase with age, from about 1% in the age group 40-49 to 20-30%⁵ in those aged over 70 indicating a greater susceptibility of older individuals to optic nerve damage. In the Collaborative Glaucoma study which followed patients prospectively, there was a trend for the elderly to develop field defects⁶ earlier at similar levels of IOP, but the reason for the susceptibility of the elderly to optic disc damage from higher pressures is not known.

Apart from age and race, there is significant individual variation in susceptibility of the optic nerve head to glaucomatous damage. While some individuals continue to have progressive optic nerve damage at relatively lower pressures (normal pressure glaucoma), others are able to withstand considerable levels of IOP before they develop optic nerve damage. Although the mere presence of elevated IOP correlates weakly with glaucomatous damage, prevalence of optic disc damage, nevertheless, rises steeply with increasing IOP⁷.

Recently, population based studies have shed light on the prevalence of glaucoma in India. The prevalence of POAG has been shown by these surveys to be similar to those in the Caucasian population. The Aravind Comprehensive Eye Survey (ACES) is a population based sample survey to identify cause specific visual impairment in rural pockets of Madurai and Tirunelveli districts of Tamil Nadu. This study had determined prevalence of POAG to be 1.4% in adults aged 40 or over. The study also identified age and IOP to be important risk factors in individuals with POAG. The age specific prevalence of glaucoma increase from 0.7% in the 40-44 years to 9.6% in those aged over 70. (*Ramakrishnan et al, presented at Annual meeting of ARVO at Fort Lauderdale, Florida, May 2000*). A majority of those with glaucoma had considerable glaucomatous damage and visual impairment when first diagnosed and 93% of individuals diagnosed with glaucoma were unaware of the poten-

tially blinding condition. 75% of those diagnosed with glaucoma in this population had severe optic disc damage and visual field loss in at least one eye at the time of diagnosis. 25% individuals were bilaterally blind by visual acuity criteria.

The Andhra Pradesh Eye Study (APEDS), a population based sample survey in urban Hyderabad had identified prevalence of POAG to be 1.62% in those aged 30 years or over. The prevalence of POAG increased significantly with age and only 7.4% of those diagnosed with glaucoma had been previously diagnosed and treated. 52% individuals with POAG had severe glaucomatous damage based on optic disc and visual field criteria and 18.5% had at least one eye blind as a result of POAG⁸ (best corrected vision less than 20/400 or central visual field loss less than 10°).

In the absence of nationwide data on the prevalence of glaucoma in India, it would be useful to use the data obtained from these prevalence studies to arrive at a rough estimate of the magnitude of the public health problem posed by open angle glaucoma. With a population of about 1026 million as estimated by the recent decennial census in 2001, about 30% (307 million) are aged over 40 years. With a modest estimate of prevalence of POAG around 1.5% in adults aged over 40 years, about 4.6 million individuals in India would have POAG. Of these, about 50% (2.3 million) would be estimated to have severe visual impairment attributable to glaucoma. Since 10% of individuals with glaucoma are estimated to be blind, 46 lakh individuals in India are expected to be afflicted by glaucoma blindness. Additionally 0.42% of those aged over 40 years (about 1.28 million) have ocular hypertension and there would be 20,000 new individuals with glaucoma every year (incidence of glaucoma among ocular hypertensives is 1.5% per year). Since increasing age is a significant risk factor, individuals with the burden of glaucoma would considerably increase in the coming decades due to increase in life expectancy and the proportion of the geriatric population.

Natural History

Glaucoma is an ocular disease with gradual and insidious loss of vision due to progressive optic nerve head damage. It is evident from eyes that have been suboptimally treated or from individuals who have sought medical help late in the course of their disease that glaucomatous damage is progressive. The pace with which optic nerve head is subject to damage from glaucoma varies with each individual depending on several factors like the level of IOP, individual susceptibility of the optic nerve, nature of intervention to lower IOP, etc, but left untreated, a large proportion with glaucoma progress to glaucomatous optic atrophy and irreversible blindness. The relationship between the level of IOP and risk of subsequent optic nerve damage suggests that it has a direct, causal or a contributory role in pathogenesis of visual loss in glaucoma. Since IOP appears to be a major risk factor in optic nerve damage, treatment aimed at reduction in IOP is expected to arrest progression of visual loss in a majority of individuals with glaucoma. In view of the dose-response relationship between IOP and damage in POAG and even in normal pressure glaucoma, it is useful to consider IOP to be the most dominant, and manipulatable variable².

Diagnosis and Clinical Features

POAG is a slowly progressive disease with insidious onset and painless loss of vision; it is bilateral but asymmetric. Central vision is relatively unaffected until late in the disease, and visual loss generally progresses without symptoms. POAG is diagnosed by assessing a combination of clinical factors, including the level of intraocular pressure (IOP), optic disc appearance and visual field damage.

History

A comprehensive evaluation of an individual with glaucoma should begin with eliciting detailed history which includes a review of the family and ocular and systemic history, use of systemic and ocular medications, past ocular surgery and known local and systemic intolerance to the use of glaucoma medications.

Clinical Evaluation

Vision and Refraction:

Best corrected visual acuity is to be determined and individuals even with advanced optic disc damage have their central acuity intact. A subnormal best corrected acuity often indicates a diagnosis other than glaucoma. Correction of refractive error is essential for accurate perimetry. Patients' refractive error occasionally aids in diagnosis. Hypermetropic eyes are at increased risk of angle closure glaucoma and have smaller optic discs. Myopia is associated with abnormal disc morphology which can be confused with glaucomatous excavation. Myopic eyes are also at increased risk of pigmentary glaucoma and POAG.

Pupils

Pupil size is affected by glaucoma therapy (miotics). Relative afferent pupil defect detects asymmetric optic nerve damage and is an important finding in glaucoma. This finding has been noted in patients with asymmetric cupping and normal kinetic visual fields⁹.

Biomicroscopy

Biomicroscopy of the anterior segment is performed to detect signs of underlying disease. Eyes with acutely elevated IOP may show conjunctival vasodilation. Chronic use of anti glaucoma medications can cause decreased tear production, allergic and hypersensitivity reactions like papillary and follicular conjunctivitis. The presence of filtering bleb indicates previous filtering surgery and its characteristics are observed.

Punctate epithelial defects, especially in the interpalpebral region is suggestive of drug toxicity. Microcystic epithelial edema is associated with acute elevation of IOP. Endothelial abnormalities like pigments, exfoliation, keratic precipitates indicate secondary causes of IOP elevation. Determination of corneal thickness is sometimes indicated when IOP measurement is inconsistent with clinical features. Abnormally thick corneas are associated with overestimation of applanation pressures and vice versa.

The anterior chamber depth is estimated with a narrow slit beam directed at an angle of 60 degrees onto the cornea at limbus (van herick method) but it is not a substitute for gonioscopy.

Evaluation of the iris is performed prior to dilation: presence or otherwise of heterochromia, atrophy, transillumination defects, ectropion uveae, corectopia, nevi, new vessels and exfoliation is observed.

The lens is generally examined after dilation. Exfoliative deposits, phacodonesis, subluxation, and dislocation should be noted along with lens size, shape and clarity.

Intraocular pressure

Population based epidemiologic studies have revealed normal mean IOP to be 16 mmHg with a standard deviation of approximately 3 mmHg. The normal range of IOP is two standard deviations above and below the mean, which is 10-22 mm Hg. IOP in general population is not Gaussian in distribution, but skewed¹⁰ toward higher pressures and an IOP > 22 mm Hg does not necessarily indicate abnormality. Most population based prevalence studies have revealed that 30-50%^{1,3,4} individuals with optic disc changes and visual field defects suggestive of glaucoma have initial screening IOP below 22 mm Hg. IOP elevation in glaucomatous eyes may occur only intermittently owing to diurnal fluctuation, so that a third of IOP measurements may be within normal limits. Normal pressure glaucoma has been recognised as a distinct entity in which typical optic disc damage and visual field loss characteristic of glaucoma is seen, but IOP does not exceed 22 mm Hg. Recent observations on ocular blood flow have shed light on the significance of perfusion of the optic disc in determining ganglion cell loss in glaucoma. Structural variations in the lamina cribrosa can also dictate the level of IOP at which glaucomatous damage is likely to occur. Owing to the contribution of several pressure independent factors in optic nerve head damage in glaucoma, the level of IOP is currently recognised as a causative risk factor in glaucoma. Higher the IOP, more is the likelihood of optic nerve damage and retinal ganglion cell loss.

IOP is preferably measured with Goldmann type of applanation tonometry or its equivalent before performing gonioscopy or dilation of the pupil. In case Goldmann tonometer is not available, Schiotz tonometer offers a viable alternative. Time of IOP measurement is to be noted.

Technique of IOP estimation

The technique of Schiotz tonometry is summarised as follows:

The patient lies supine and fixates on an overhead target, or the patient's thumb itself could serve as a fixation target. A topical anaesthetic is instilled in each eye. After explaining the nature of the procedure and reassuring the patient, the examiner retracts the lids without undue pressure on the globe. The footplate of the tonometer is placed gently on the apex of the cornea and the reading on the scale is observed. If the reading is less than 3 scale units, additional weight is placed on the plunger. The average scale reading is converted to intraocular pressure in millimeter of mercury using a conversion chart. The instrument is calibrated before each use by placing it on a metal surface and checking that scale reading is zero.

Goldmann tonometry is accurate and reproducible. Interobserver variability is reported to be between 0-3 mmHg which is well within diurnal fluctuation of IOP. The technique applanation tonometry is as follows:

A drop of topical anaesthetic is placed in each eye and the tip of moistened fluorescein strip is touched to the tear film on the inner aspect of the lower lid. The tonometer and prism are set in correct position on slit lamp. The tension knob is set at 1g and the 0 graduation mark of the prism is set at the white line on the prism holder. The cobalt filter is used with the slit beam opened maximally. The angle between the illumination and microscope is 60°. The patient is comfortably seated on the slit lamp and the tonometer prism is advanced until the tip of the prism touches the cornea. A monocular view of the central applanated zone and the fluorescein stained tear film is obtained. The tip of the applanation prism is adjusted until two equal semicircles are seen in view. The fluorescein rings are approximately 0.25-0.30 mm in thickness. If fluorescein rings are thinner, IOP is underestimated and additional fluorescein may be added. A wide fluorescein ring may over estimate IOP and excessive dye is dried with a tissue and IOP is re estimated. The tension knob is rotated until the inner border of fluorescein rings approximate. The reading obtained is multiplied by 10 to give the IOP in millimetres of mercury. IOP is measured in each eye until three consecutive readings are found within 1 mm Hg.

Optic Disc evaluation

Careful assessment of the optic disc is an essential aspect of clinical evaluation for glaucoma and additionally, fundus evaluation may reveal posterior segment abnormalities such as haemorrhages, effusions, retinal vascular occlusions, diabetic retinopathy inflammation, tumour or retinal detachment that may be associated with glaucoma. Fundus and optic disc evaluation is best performed with a dilated pupil.

The optic nerve head can be evaluated clinically using a direct ophthalmoscope, an indirect ophthalmoscope or a slit lamp biomicroscope using a posterior pole lens. The instrument is most commonly used to examine the optic disc is the direct ophthalmoscope, which is simple to learn and use and is inexpensive when compared to other techniques. It can be used to study the optic disc fairly easier even in eyes with small pupils and can be used with a red free filter to study the retinal nerve fiber layer. The direct ophthalmoscope has a distinct disadvantage in that it does not provide sufficient stereopsis to detect subtle changes of the optic nerve head topography in early glaucoma.

The optic nerve head is preferably evaluated using a slit lamp biomicroscope and a posterior pole lens (90 D or a 78 D lens) or a Hruby lens which offers a stereoscopic and a magnified view of the optic nerve head and retinal nerve fiber layer. The slit beam, rather than diffuse illumination is useful in detecting changes in the contour of the optic disc. These techniques require patient cooperation and pupillary dilation for an adequate view of the optic disc details. An Indirect ophthalmoscope can be used for evaluation of children, unco-operative patients and in eyes with media haze, but this method does not provide adequate magnification to study subtle or localised details of the optic disc that is vital in early diagnosis of glaucoma.

The optic disc is in round or slightly oval in shape, and it contains a central area of pallor, the optic cup. The tissue between the cup and the disc margin is the neuro retinal rim, which in normal patients has a relatively uniform width and color that ranges from orange to pink. The neuro retinal rim is composed of the axons of the retinal ganglion cells as they exit the eye through the optic nerve. Death or destruction of the retinal ganglion cells, as in glaucoma is reflected in loss or thinning of the neuro retinal rim and enlargement of the optic cup.

The size of the physiologic optic cup is genetically determined and is related to the size of the optic disc. For a given number of axons of the retinal ganglion cells, which is constant in humans, larger the overall disc area, larger the cup. The cup to disc ratio may slightly increase with age. Individuals with myopia have larger eyes and optic discs and cups than emmetropes or hyperopics.

Ophthalmoscopic signs of glaucoma are

Generalised

- Large optic cup.
- Asymmetry of cups between eyes.
- Progressive enlargement of the cup.

Focal

- Narrowing (notching) of the neuro retinal rim
- Vertical elongation of the cup.
- Cupping to the rim margin.
- Regional pallor.
- Splinter haemorrhage.
- Nerve fiber layer loss.
- Bayonetting of retinal vessels.
- Overpass vessel phenomenon.

Non specific signs of glaucomatous damage

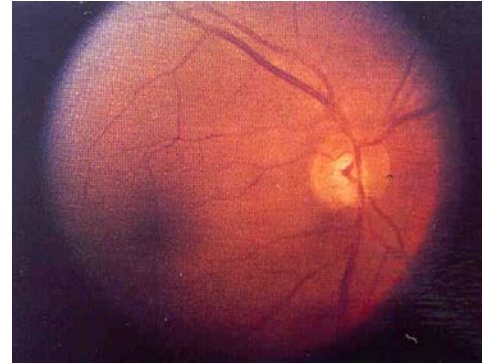
- Exposed lamina cribrosa (laminar pore sign).
- Nasal displacement of retinal vessels.
- Baring of circumlinear vessels.
- Peripapillary crescent.

Generalised enlargement of the cup may be the earliest change detected in glaucoma. Focal enlargement of the cup appears as localised notching or narrowing of the neural rim. Deep and localised notching where lamina cribrosa becomes visible at the disc margin is referred to as the acquired optic nerve pit. The cup becomes vertically oval if notching or acquired pit occurs at one or both of the inferior and superior aspect of the optic disc. Notching or thinning and loss of neuro retinal rim is associated with bayonetting of retinal vessels.

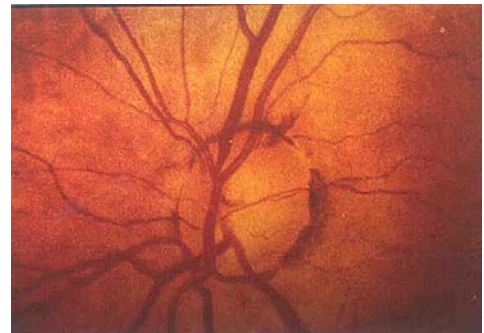
Disc haemorrhages appear as a linear red streak at or near the disc margin. The haemorrhage is evanescent and clears over several weeks to months but is followed by localised notching and pallor of the rim and visual field loss. Individuals with normal pressure glaucoma are more likely to have such splinter haemorrhages¹¹ than those with POAG. Most eyes with disc haemorrhages tend to have progressive field loss and hence are a reliable prognostic sign.

Retinal Nerve Fiber Layer

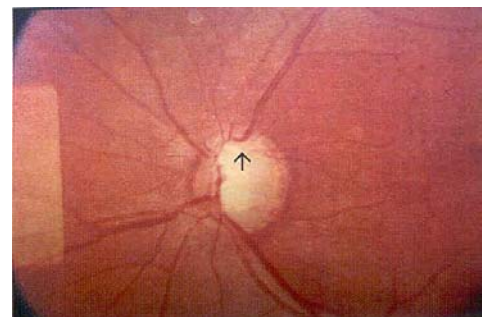
Glaucomatous optic atrophy is associated with loss of axons in the nerve fiber layer. In normal eyes, nerve fiber layer is best visualised with red free illumination and appears as a pattern of striation that radiate toward the optic disc. With the ganglion cell loss that occurs in glaucoma, the nerve fiber layer thins and becomes less visible. These appear either as dark stripes or wedge shaped defects of varying width in the peripapillary area, paralleling



Glaucomatous optic disc excavation with inferior retinal nerve fibre layer defect



Glaucomatous optic disc excavation with splinter haemorrhage



Advanced optic nerve damage due to glaucoma

the normal retinal striations, or as diffuse loss of striations and correlate well with field changes¹⁷. The retinal nerve fiber defect may be diffuse or localised to specific bundles of axons and may be the initial sign of glaucomatous damage¹⁸. Focal abnormalities consist of slit like grooves or wedge defects. Slit like defects are common in normal eyes and they do not extend upto the disc margin. Diffuse nerve fiber loss is more common in glaucoma than focal loss but are also difficult to be appreciated. Observation of the optic disc is the key aspect in the clinical examination of glaucoma and the evaluation of the peripapillary retinal nerve fiber layer can provide additional useful information. Direct and indirect ophthalmoscopy and slit lamp can be used to evaluate the retinal nerve fiber layer and a combination of a posterior pole lens at the slit lamp, wide slit beam and a red free filter offer the optimal view for its detailed study. More objective and quantitative analysis of the optic nerve head and the retinal nerve fiber layer are possible with the recently introduced image analysis systems like the confocal laser scanning ophthalmoscopy and optical coherence tomography.

Perimetry

Perimetry refers to the clinical assessment of the visual fields and principally serves the twin objectives in the management of glaucoma:

- Identification of abnormal fields characteristic of visual loss in glaucoma.
- Quantitative assessment of normal or abnormal visual fields to follow up progression of the optic disc damage in glaucoma.

Clinical Perimetry

Two main types of perimetry are currently in use in evaluation of patients with glaucoma:

- Manual kinetic and static perimetry using a Goldmann type Bowl perimeter.
- Automated static perimeter.

Patterns of Glaucomatous Field loss

Glaucomatous field damage results from injury to the intraocular portion of the optic nerve extending from the retinal ganglion cells to the lamina cribrosa. Axonal damage is the cause of defects in glaucoma and the pattern of visual field loss reflects the pattern of distribution of the axons of the retinal ganglion cells in the retina.

Generalised or diffuse field loss is due to diffuse loss of axons while localised field defects are due to injury to a contiguous group of axons. Scotomata or localised depression of visual field are more easily recognised than generalised depression.

Generalised depression can be the earliest sign of glaucoma but is non specific since it can occur with aging, miosis and media haze. It can however increase a clinician's suspicion if unilateral and more pronounced in the eye with higher IOP or larger cup to disc ratio. It is seen as generalised constriction of isopters in manual kinetic perimetry and as a generalised reduction in retinal sensitivity in thresholded static automated perimetry.

Irregularity of visual fields

The roughness or irregularity in visual fields appears in computerised perimetry as a variation of retinal sensitivity among the contiguous points that is greater than expected in the age corrected normals. Statistically, this variation is expressed as the standard deviation of the mean of all points tested (pattern standard deviation, Humphrey perimeter) or the variance of square of standard deviation of the mean of the points tested (loss variance, Octopus perimetry).

Nasal step or depression

The nasal portion of the visual field is affected early in glaucoma. It is evidenced by inward turning of the isopter in the nasal aspect in manual perimetry or by reduced sensitivity in static perimetry. These defects may occur centrally, peripherally or may be isolated or associated with arcuate scotoma.

Temporal step or depression

A temporal step or depression may be seen in about 5% of individuals with glaucoma and Drance suggests careful assessment of the temporal visual fields to detect the occasional individuals in whom this may be the only visual field defect present.

Isolated paracentral scotoma

Aulhorn and Harms have found paracentral scotomas in 20% glaucomatous visual fields, which may be the earliest manifest field defects specific for glaucoma. If glaucoma is progressive, these paracentral defects enlarge, deepen, and coalesce to form arcuate scotoma.

Arcuate scotoma (Nerve fiber bundle defects)

The arcuate scotoma represents a complete retinal nerve fiber bundle defect which begins at one of the poles of the blind spot, arcs around fixation, and terminates with a nasal step at the horizontal raphe. The defect may break through to the periphery nasally and further progress to become an altitudinal defect.

End stage glaucoma defects

In an advanced state of glaucomatous damage, most axons at the superior and inferior aspect of the optic disc is damaged, leaving only the papillomacular bundle and some nasal fibers. This results in the typical end stage glaucoma defects with a small central island and a large crescent of temporal island remaining. The central island may also be characterised by split fixation and eyes with such defects, are susceptible to central visual loss following filtering surgery.

A computerised perimeter determines threshold sensitivity at multiple pre determined points in the visual field in a reasonable amount of time and presents results in a comprehensible form that can be statistically analysed, stored and retrieved for comparison on a later date. The widely employed instruments are the Bowl perimeters that project the stimulus in programmed locations. The intensity of stimulus is varied by a system of filters that attenuate the stimulus allowing measurement upto 1 dB.

Threshold testing is currently the most preferred method of visual field analysis in glaucoma diagnosis and management. Threshold is determined at specific, predetermined locations in visual field space using variety of bracketing or statistical strategies. Several points are re tested to determine patients' variability in responses (short term fluctuation) and occasional checks are performed to monitor fixation and assess frequency of patient's false positive and false negative responses.

The most common programs for glaucoma testing are the central 24 and 30 degrees programs such as the Octopus 32 and G1 and the Humphrey 24-2 and 30-2. They test the central fields using a 6 degree grid and also points 3 degree above and below the horizontal midline and facilitate diagnosis of defects that respect this line.

Interpretation of visual fields in glaucoma

A cluster of two or more points with sensitivity depressed³ 5dB compared with neighbouring points in a location in visual field prone for glaucomatous damage is highly suspect. In interpretation of the numerical data generated by the threshold tests, various field indices have been introduced. The Humphrey pattern standard deviation and the Octopus loss variance which indicate localised depression in visual field and aid in differentiating from generalised reduction in retinal sensitivity. An abnormal pattern standard deviation has more diagnostic significance than a generalised loss of sensitivity. An abnormally high pattern standard deviation indicate that some points in visual field are significantly depressed relative to the rest of the field and is suggestive of focal damage such as that seen in glaucoma. Generalised loss of retinal sensitivity may also occur with diffuse glaucomatous damage.

Gonioscopy

Gonioscopic evaluation of the anterior chamber angle is an essential diagnostic tool in glaucoma. Acquiring precise gonioscopic skills is also essential for treatment in the angle (eg. laser trabeculoplasty, goniotomy, management of a failing filtering bleb, etc). It is performed as a part of initial evaluation of a patient with glaucoma and also repeated at periodical intervals.

The angle structures cannot be viewed under normal circumstances since the light rays from the angle undergoes total internal reflection at the cornea-tear film-air interface. A Gonioscopic lens eliminates this interface and replaces it with a new lens-air interface set at a different angle to the emerging light rays, to enable the view of the angle.

Goldmann gonioscopic lens is the prototype instrument employed in viewing the anterior chamber angle.

Technique

The patient sits with the head firmly against the headrest of the slitlamp and a local anaesthetic (4% lignocaine) is instilled. 1% methylcellulose solution is placed on the corneal aspect of the gonioscopic mirror. With the patient looking up, one edge of the lens is placed in the lower fornix, the upper lid is elevated, the patient is instructed to gaze straight and the lens is rotated against the eye. An inverted image of the opposite angle is viewed in the mirror. The scleral spur and the Schwalbe's line are the most consistent angle landmarks which could be used for identification of the angle structures and their grading. Schwalbe's line can be identified as the termination of the corneal light wedge; using a narrow slit beam sharply focused, one could observe two linear reflections, one from the external surface of the cornea and its junction with the sclera, and the other from the internal surface of the cornea. These two reflections meet at the Schwalbe's line. The scleral spur is identified as a thin stripe between the ciliary face and the pigmented trabecular meshwork. The width of the angle is determined by the site of insertion of the iris on the ciliary face, convexity of iris and the prominence of the peripheral iris roll. The Shaffer system of grading the anterior chamber angle has been widely employed.

Follow up Glaucoma evaluation

The principle objective of follow up evaluation in subjects with glaucoma is to assess the response to therapy and ensure that further functional loss of vision is arrested. The treatment may be altered or adjusted according to the features of the follow up evaluation, which will basically monitor the following parameters:

- Intraocular pressure.
- Optic disc appearance.
- Visual fields- require frequent retesting because of inherent fluctuation in patient response and to validate apparent or true deterioration in visual fields over time.
- Adverse effects, compliance to therapy.
- Gonioscopy is periodically performed to exclude angle closure component, especially if miotics are recommended for lowering IOP.

The frequency and composition of the follow up evaluation depends upon the severity of existing optic nerve damage, range of IOP fluctuation and stability of the clinical course.

In case of an unstable, uncontrolled IOP or deterioration of optic nerve status, it may be necessary to examine the patient relatively more frequently. Depending on severity of damage, the patient may need to be seen on a daily or weekly basis until appropriate stability is achieved. IOP is recorded on all visits and the optic nerve head appearance and functional status (visual fields) need to be periodically assessed. In case of moderate to severe optic nerve damage, the follow up evaluation is performed once in 2-6 months depending on documented control and the level of IOP. A visual field analysis and optic nerve head appearance is documented 2-3 times each year. Follow up and documentation of findings could be performed less often, in case of minimal damage to optic nerves from glaucoma, provided the ocular pressures have been in the target range, considered safe for the optic nerve.

Treatment

Lowering the intraocular pressure remains the cornerstone of management of glaucoma. Available evidence and clinical experience seem to suggest that progression of optic nerve head damage and visual loss is largely preventable^{19,20} with adequate lowering of IOP. Although a third to half of patients with glaucoma seen in epidemiologic studies have normal IOP at the time of diagnosis, a significant percentage of these were detected to

have elevated IOP at some point of time. The Normal tension glaucoma study had revealed that lowering IOP in individuals with glaucoma with ocular pressures in the statistically normal range helped delay further glaucomatous visual field loss.

Odberg²¹ provided additional proof of the profound influence of the level of IOP on progression of glaucoma. Only 33% of eyes with IOP < 16 mmHg revealed progressive optic nerve damage in contrast to 84% of individuals with IOP³ 20 mmHg. Kolker²² had found 4% individuals with advanced glaucoma lost central vision with an average IOP below 18 mmHg, while 19% lost vision with an IOP of 18 to 22 and 29% lost vision with an IOP exceeding 22 mmHg.

The management of a patient with POAG is essentially summarised in the following steps:

- Establish a baseline (by a comprehensive initial baseline diagnostic evaluation)
- Set a target intraocular pressure as a goal for therapy.
- Institute appropriate treatment to lower IOP.
- Follow up the patient at periodical interval to see if the target IOP is achieved and maintained by therapy and also if the disease is stable or progressive.
- Modify or reset the target IOP and the treatment as dictated by the patient's clinical course and response to treatment.

Target Pressure in glaucoma:

For every individual with glaucoma, there is perhaps a level of IOP at which progression of glaucomatous damage is acceptably low. This IOP level, then represents the threshold for damage to that patient. The higher is the IOP is, above this threshold level, more rapidly will the glaucomatous damage progress. The stable range of ocular pressures that is deemed unlikely to cause further optic disc damage is referred to as the target intraocular pressure. This target pressure varies between patients and likely to vary during the course of the disease, in the patient.

When instituting therapy to lower IOP, one assumes that the pretreatment IOP is that which has damaged the optic nerve and would continue to result in additional loss of retinal ganglion cells. A target IOP is set, based on the existing damage to the optic nerve and the visual field, the height of the IOP and the rapidity with which the current damage has presumably occurred. There is no way by which the target pressure in a given patient will be precisely determined as the initial target pressure set is only a best estimate and a means to protect the optic nerve. Failure to achieve the pressure goal or further damage it, despite achieving the preset pressure goal should stimulate reassessment of the treatment regimen with an eye on the potential risks and benefits of such additional or alternative therapy.

Although there are no well defined guidelines in trying to choose the target IOP, the *American Academy of Ophthalmology*²³ has some recommendations:

The severity of the glaucomatous damage is graded based on the optic disc status and the visual fields.

Mild - Characteristic optic nerve damage consistent with glaucoma, but the visual field is normal.

Moderate - Visual field defect is restricted to one of the hemifields, and are not within the 5 degrees of fixation.

Severe - Visual field abnormalities are in both the hemifields or within 5 degrees of fixation.

Based on this grading of severity of glaucomatous damage, a 20% reduction in IOP is presumed to be reasonable in mild damage, and a 30% reduction in moderate loss. In eyes with severe damage, a 35-40% reduction in IOP is deemed appropriate. In eyes with very advanced optic disc damage or glaucomatous field loss, it is recommended that IOP be maintained below 15 mmHg or even in the low teens.

Treatment Options

IOP can be lowered to a variable extent and duration by medical, laser or operative treatment (either alone or in combination). Medical agents include miotics and prostaglandin analogues that increase aqueous outflow, beta receptor antagonists, alpha agonists and carbonic anhydrase inhibitors that suppress aqueous formation.

Argon laser trabeculoplasty involves laser treatment of the trabecular meshwork that enhances aqueous outflow by mechanisms that are poorly understood, but its IOP lowering efficacy over long term remains contentious. Glaucoma filtering procedures provide a low resistance, alternate pathway for flow of aqueous. Ciliodestructive procedures reduce aqueous humour formation, but are not routinely employed as a primary procedure in management of glaucomas.

Glaucoma is a chronic condition and patients require continued care for life to preserve useful visual function. Every form of treatment involves some cost and has potential risks and adverse events. The treatment chosen to reduce the IOP needs to be highly individualised, and may depend upon the patient's physical, visual, medical, psychological and social status as well as the level of damage, height of IOP, age and life expectancy of the patient. The goal of treatment in glaucoma is provision of an intervention or therapy that will offer greatest benefit to the patient at the lowest possible cost and inconvenience to the patient and the least possible risk.

Initial Treatment Plan

Once the pressure goal has been determined, treatment is instituted to achieve this pressure goal. Each of the available option of treatment has merits and demerits and the precise choice of initial therapy and the appropriate order in which the treatment is stepped up or altered is subject to dispute. The three major options that are currently available are:

Start treatment with topical medications: Step up or substitute different class of medications if target IOP is not reached. If a combination of medications fail to achieve sufficient IOP lowering, perform argon laser trabeculoplasty and sequentially, a glaucoma filtering procedure.

Perform laser trabeculoplasty: and follow up treatment failure by adding ocular hypotensive medications. Filtering surgery is finally performed if these conservative techniques fail to achieve adequate lowering of IOP.

Perform filtering surgery as a primary treatment: Failure to lower IOP is followed by institution of sequential medical therapy and laser trabeculoplasty.

Medications as Initial Therapy

The most commonly followed traditional approach in the management of glaucoma, the world over is the institution of medical treatment. Topical medications control IOP adequately in most patients. They can be altered or discontinued with ease, and do not cause acute ocular complications as in the case of laser or operative treatment. Systemic and ocular adverse reactions with topical medications are likely, but are largely avoided with a careful medical history and a physical examination. If a combination of medical treatment fail to achieve IOP lowering, laser trabeculoplasty and filtering surgery are attempted.

Medical treatment of glaucoma is not without its drawbacks. Ocular medications involve considerable expense and are bothersome to use. Poor compliance to medical treatment is a frequent cause of failure of therapy. Non compliance²⁴ has been estimated to cause about 10% of all visual loss from glaucoma and is a major cause of blindness. All drugs have potential ocular and systemic side effects and regular medical therapy is likely to influence the quality of life of patients adversely. Prolonged use of medications²⁵ promote inflammatory changes in the conjunctiva that may adversely influence the success of subsequent filtering surgery.

Laser Trabeculoplasty as Initial Treatment

Laser trabeculoplasty lowers IOP in most patients with POAG. It may reduce, delay or eliminate the need for subsequent medical therapy to lower IOP. It exerts its effects throughout the day and success of therapy does not depend on patient compliance. When ineffective, drug therapy or operative intervention may supplement laser trabeculoplasty.

Laser trabeculoplasty often has only a temporising effect on IOP reduction due to loss of efficacy over time. Most individuals initially treated with laser require additional medical therapy. Approximately only 50%²⁶ of the individuals treated, maintain IOP lowering efficacy for five years. Acute elevation of IOP following laser has been reported to result in additional optic nerve damage. Chronic IOP elevation is a likely complication, requiring, filtering operations to control the IOP, which otherwise would not have become necessary.

Glaucoma Filtering Surgery as Primary Intervention

A successful filtering surgery, by a single intervention, achieves lower IOP than by medical or laser treatment with long term stabilisation of visual fields and acuity. It also offers a 24-hour control of IOP and patient compliance is not a factor in success of therapy. The success of primary surgery is likely to be higher since long term use of topical medications result in inflammatory changes in the conjunctiva which promote bleb fibrosis and filtration failure. Medications and laser may be used to contain IOP if surgery fails. Over long term, surgical treatment is also cost effective, since it involves fewer follow up visits to monitor progression and obviates the need for medications. In a study of 105²⁷ eyes with a follow up of five years, IOP control was superior with trabeculectomy as compared to laser or medical therapy.

Surgery is not successful in all individuals and initial success may be reversed after a few years in still others. Intraocular surgery also carries risk of infrequent, but potentially blinding complications, like hypotony, hemorrhage and infections. The presence of a filtering bleb, especially with the use of antimetabolites, places the eye at risk of bleb related endophthalmitis. Cataracts progress rapidly after filtering operations and subsequent cataract operations hasten filtration failure.

Suggested Approach for Initial Management of POAG

Most studies that have highlighted the benefits of early surgery and laser trabeculoplasty had been conducted in the past decades when most of the new generation ocular hypotensive drugs which are potent and well tolerated, were not available. These trials had been conducted in the west, where glaucoma is generally believed to be diagnosed early in the course of the disease and patients are expected to be better compliant than their counterpart in the third world. The results of these studies, could hence be not applied in the setting of developing countries like India. Initial therapy with medications is the most favoured and acceptable approach the world over. Even in individuals with advanced glaucomatous damage and high IOP, if primary filtering surgery is contemplated to achieve target IOP, a trial of medical therapy is indicated to control IOP prior to surgery. This approach may minimise progressive optic nerve damage and visual field loss in the eye scheduled for surgery as well as in the fellow eye. A good response to medical therapy in some individuals may unexpectedly obviate the need for further surgery, provided the drugs are well tolerated and the patient extremely compliant.

Initial Medical Management

Selection of an ocular hypotensive agent is preceded by a review of patient's medical history, allergies, systemic illnesses and experience with previous glaucoma medications. Beta blockers are contra indicated in patients with asthma, chronic obstructive pulmonary disease (COPD) or bradycardia. A beta-1 selective agent like betaxolol reduces incidence of pulmonary adverse effects. Carbonic anhydrase inhibitors are avoided in patients with known sulphur allergies and history of nephrolithiasis. Ocular conditions also affect choice of medications. Latanoprost is best avoided in individuals with pseudophakia and uveitis due to its propensity to cause cystoid macular edema (CME). Cholinergic agents cause miosis and reduce acuity in eyes with central lens opacities.

In the absence of medical contraindications, a non selective beta blocker like timolol²⁸ is the drug of choice for initial medical therapy. These drugs have been in use for over two decades, are well tolerated and their side effect profile is well documented. Unlike miotics, they do not affect pupil size or accommodation. In patients with mild asthma or COPD beta-1 selective drug like betaxolol is a safer alternative.

Miotics, like pilocarpine, are indicated as first line therapy when beta blockers are contraindicated. They are relatively inexpensive and have few systemic complications. The disadvantages of this class of drugs is principally their ocular side effects. They cause miosis and spasm of accommodation which blur vision and make evalu-

ation of disc and visual field evaluation difficult, especially in presence of central lens opacities. Their prolonged use cause posterior synechiae, cataracts, anterior chamber shallowing and angle closure and probably contribute to retinal breaks and retinal detachment. The drugs need to be used three to four times a day for optimal IOP lowering, which may decrease patient compliance. Although miotics are less popular than beta blockers due to their adverse effect profile and frequent dosing schedule, they are employed in specific situations, such as when beta blockers are contra indicated or not tolerated, especially because the newer ocular hypotensive drugs are relatively expensive.

Latanoprost is an excellent alternative in individuals in whom beta blockers are contraindicated or miotics are not well tolerated. It is a prostaglandin analogue which increases uveoscleral outflow and profoundly reduces IOP when dosed once daily. An average reduction of IOP by 8 mmHg was reported by the latanoprost study²⁹ and no systemic side effects were observed. An increase in iris pigmentation, hypertrichosis and cystoid macular edema were ocular adverse effects.

Brimonidine is an alpha-1 receptor agonist and is also a viable alternative choice, in case beta blockers or pilocarpine cannot be used. Brimonidine reduces aqueous secretion and is also claimed to enhance uveoscleral outflow and have optic nerve neuroprotective properties. In a one year study comparing timolol and brimonidine³⁰, both drugs maintained significant IOP reduction at peak, although timolol had significantly better IOP lowering at trough at all follow up visits. Brimonidine has less cardiopulmonary side effects than beta blockers and individuals with systemic contra indications to betablockers may benefit from brimonidine as initial therapy.

Topical carbonic anhydrase inhibitors like dorzolamide³¹ and brinzolamide have been known to have IOP lowering potency similar to that of timolol, but need to be administered two to three times a day for maximal efficacy. The primary advantage of these drugs is that they are devoid of the systemic side effects characteristic of oral carbonic anhydrase inhibitors like acetazolamide. These drugs are not available for use in India, although a topical form of 5% acetazolamide has recently been introduced. This drug has not been evaluated in long term clinical trials to justify its use as a primary drug in management of glaucoma. Oral acetazolamide causes gastrointestinal disturbances, paraesthesiae, metabolic acidosis, electrolyte disturbances, nephrolithiasis and bone marrow depression, which preclude their use for chronic therapy of glaucomas.

Regardless of which drug is chosen, the treating ophthalmologist should aim at achieving the target IOP range to ensure stability of disease. Although there is evidence to suggest that an IOP \leq 12 mmHg usually prevents further glaucomatous progression, it is reasonable to aim for a 20-30% reduction in the initial pretreatment IOP. However, it is by trial and error and by repeated follow up and observation that a clinician is able to constantly readjust the treatment appropriately and get as closer as possible to the target IOP. A monocular drug trial may be employed to reveal if a particular drug is effective in reducing IOP. Acceptable reduction in eye pressures is followed up by treatment of the fellow eye. In patients with high pressures and considerable optic nerve damage, monocular trial may not be appropriate. Aggressive therapy is indicated if IOP rises to levels previously associated with disease progression. Loss of efficacy of drug or true progression of disease may be the cause of rise in IOP. This situation is tackled by addition or substitution with an alternate class of ocular hypotensive drugs

The tendency to add more medications, presuming that it is necessarily better, is generally discouraged. Adding new drugs imply potentially additional side effects, drug or preservative allergies and inconvenience because of multiple dosing. Where possible, substitution with an alternate class of drugs is attempted, especially when there is loss of drug efficacy. Adding multiple drugs is more appropriate when progression of optic nerve excavation is documented in spite of reduction in IOP. Non selective beta blockers like timolol are the most widely prescribed first line drug and it has been revealed by clinical studies that drugs like pilocarpine, brimonidine, latanoprost and carbonic anhydrase inhibitors have additive IOP lowering potency when combined with timolol.

The Surgical Option in POAG

A surgical procedure is indicated when medical therapy no longer controls IOP adequately or there is progressive glaucomatous damage to the optic nerve or visual field. In the developed society like the US, a failure of maximal tolerated medical therapy is sequentially followed by laser trabeculoplasty and filtering surgery. The principal

advantages of laser trabeculoplasty include the fact that it is less invasive than fistulising surgery and the procedure reduces IOP in approximately 85% of the patients treated and has an efficacy of about 50% at 5 years²⁶. The IOP lowering ranges between 20-30% with a mean fall of 9 mm Hg³². Trabeculoplasty reduces the number of medications required to control IOP, especially when multiple drugs are indicated or when patients are intolerant to some medications. It is generally believed that combination of laser trabeculoplasty and medical therapy is superior to medications in control of IOP. Several clinical studies in the west have concluded that laser trabeculoplasty delays or obviates the need for incisional surgery in a considerable proportion of patients. The Advanced Glaucoma Intervention Study (AGIS)⁵⁰ has however revealed a differential response to a specific sequence of laser trabeculoplasty and trabeculectomy between the white and the black race. The role of trabeculoplasty in management of glaucoma in the Indian population has not been prospectively studied. In the absence of effective screening strategies, patients present considerably late in their course of the disease, and the role of laser trabeculoplasty is not well defined in this population. Since the efficacy of trabeculoplasty is short lived and laser does not eliminate the need for medical therapy, incisional surgery is generally preferred by ophthalmologists in India when maximal tolerated medical therapy fails to achieve the target IOP. Eyes with very high IOP and advanced damage are unlikely to achieve sufficient IOP lowering with laser trabeculoplasty. Failure of medical therapy may be a consequence of noncompliance which is a relative indication for surgery.

Trabeculectomy is the most preferred glaucoma filtering surgery and has been reported to contain glaucomatous damage in 75-95%^{33,34,35,36} of eyes. The use of anti metabolites like mitomycin^{40,41,42} and 5 fluorouracil^{37,38} results in lower IOP and prolonged bleb survival but also results in increased incidence of complications like cataracts, shallow chambers, hypotony and maculopathy and endophthalmitis. A one year dose response study of mitomycin in glaucoma filtering surgery in Madurai³⁹, India had revealed enhanced filtering success following mitomycin augmented trabeculectomy, but had also resulted in significantly increased lens opacification (14%). Indiscriminate use of antifibrotic agents are to be avoided and should be applied with extreme caution in primary trabeculectomies and in young myopes owing to an increased risk of hypotony.

Patients are to be clearly explained the purpose and expectations of glaucoma filtering surgery: to arrest or delay progressive visual loss due to glaucoma. Glaucoma surgery hardly improves vision and glaucoma medications may still be required postoperatively as surgery may fail or vision could be lost totally and glaucoma may progress despite successful surgery. Individuals with advanced field loss splitting fixation are at risk of losing central vision following surgery, possibly due to cystoid macular edema, IOP spike, shifting of lamina cribrosa further damaging residual axons or optic nerve ischaemia.

Trabeculectomy Technique

Trabeculectomy is a guarded partial thickness filtering procedure performed by excising a block of limbal tissue beneath a lamellar scleral flap. The scleral flap provides resistance and limits excessive flow of aqueous, thus reducing complications such as flat chamber, cataract, serous and haemorrhagic choroidal effusion and hypotony.

Successful glaucoma filtering surgery involves prolonged reduction in IOP without complications that compromise visual outcome. It depends on appropriate post operative intervention to modulate and enhance the function of the bleb. Successful outcome depends on complete healing of conjunctival and epithelial wound healing with incomplete healing of the scleral wound. The use of antifibrosis, combined with techniques of releasable sutures or laser suture lysis promotes bleb function with lower IOP and minimises complications associated with full thickness procedures.

The surgical technique of trabeculectomy essentially consists of the following steps:

Conjunctival flap

A fornix based or limbus based conjunctival flap is preferred. The fornix based flap is easier to perform and provides better exposure, though a watertight closure is difficult to achieve. The limbus based flap allows secure closure of the conjunctiva, though is difficult to perform. The conjunctival wound is positioned 8-10 mm posterior to limbus and care is taken to avoid injury to superior rectus tendon or anterior ciliary vessels.

Scleral flap

The exact size and shape of the lamellar scleral flap is not critical and is individual surgeon's preference. Care should be taken to avoid overlapping of the scleral flap edges by the underlying internal sclerostomy window. A common technique comprises a 3-4 mm triangular or rectangular flap dissected anteriorly into the cornea. Most surgeons prefer to excise a corneal wedge of tissue underneath the scleral flap since posterior dissection increases risk of bleeding from iris root and ciliary body.

Paracentesis

A 26-gauge needle is used to perform a clear corneal paracentesis which allows gradual decompression of the globe, control of anterior chamber depth and IOP by infusion of balanced saline or viscoelastic and intraoperative testing of patency of filtering site and integrity of scleral flap and conjunctival closure. Balanced saline solution is injected as the scleral flap sutures are adequately added to ensure controlled flow of aqueous. In case of post operative shallow chambers, the paracentesis track is utilised to reform anterior chamber by injecting saline or viscoelastic.

Internal sclerostomy

The internal fistula or window is created by Kelly's punch or by sharp dissection using Vannas' scissors. Theoretically, an opening of 125-250 μ is sufficient for unimpeded flow of aqueous, but practically, a 1-2 mm opening is dissected beneath the partial scleral flap. To prevent excessive flow of aqueous and hypotony, it is essential to scrupulously avoid overlap between the edges of the scleral flap and the internal ostium.

Iridectomy

An iridectomy is essential to prevent post operative pupillary block and also to avoid occlusion of the internal sclerostomy window by peripheral iris. It is not necessary for the iridectomy to be truly basal, and care is taken to avoid injury to ciliary processes, zonular fibers or hyaloid face.

Closure of scleral flap

This is a crucial step in glaucoma filtering surgery. Too tight closure of the flap or too many sutures may result in high IOP due to inadequate aqueous flow and eventual failure of filtration. Too loose suturing or inadequate sutures would result in hypotony. With the advent of laser suture lysis and releasable sutures, most surgeons prefer tight closure of the flap with graded filtration post operatively. Use of antimetabolites in the recent years has also allowed tight flap closure with post operative suture lysis depending on the amount of filtration. Flow of aqueous around the flap is checked for excess leakage around the flap before conjunctival closure. Leakage is adjusted by addition of sutures, removal of sutures or by carefully cauterising the edges of the scleral flap intraoperatively.

Conjunctival closure

Forinx based flap is secured at the limbus by interrupted sutures. Limbus based flap is closed by approximating the tenon's layer and conjunctiva separately. Meticulous and watertight closure of the conjunctiva is vital to prevent wound leak, flat chamber and hypotony. The conjunctiva is carefully inspected to exclude button holes and tears, which are immediately repaired. Subconjunctival dexamethasone and a broad spectrum antibiotic like gentamicin and topical atropine are instilled.

Post operative considerations

Topical corticosteroids, antibiotics and cycloplegics are instilled. Systemic or sub tenon's steroids are indicated to reduce inflammation and scarring in eyes with high risk of failure from scarring. Steroids are gradually tapered over a period of 10-12 weeks if the post operative course is uneventful. Frequent follow up over the first few weeks facilitates assessment of the bleb function. Poor functioning of the bleb as evidenced by higher IOP or flat bleb despite digital pressure is indication for laser suture lysis or removal of releasable sutures. Filtration is best enhanced if suture lysis or release is performed within a fortnight before the conjunctiva has fibrosed. Premature suture release has to be meticulously avoided when antifibrosis has been employed to prevent complications like overfiltering. The use of antifibrotic agents allow a greater window of time period, even several months, before sutures can be lysed or released.

Complications

Early complications of glaucoma filtering surgery include hypotony⁴³, flat chambers due to excessive filtration, choroidal detachment⁴⁴, uveitis, hyphaema, suprachoroidal haemorrhage⁴⁵ and loss of central island⁴⁶ of vision. Long term complications include filtration failure from bleb fibrosis, bleb leak, chronic hypotony, cataract progression⁴⁷, bleb infection and endophthalmitis⁴⁸. The risk of bleb related complications are higher when anti metabolites are used to retard bleb scarring.

Provider and Setting

Diagnostic procedures like refraction, tonometry, perimetry and fundus photography may be delegated to appropriately trained and supervised para medical personnel. The interpretation of the diagnostic procedures and management of disease remains the obligation of highly trained and skilled ophthalmologists. Diagnostic and therapeutic procedures are safely undertaken on an outpatient basis. Hospitalisation is required for surgical intervention and laser procedures such as trabeculoplasty which entail high risk of complications in individuals with advanced glaucomatous visual loss and in patients in whom complications have occurred after surgical procedures or patients with specific medical and social needs.

Health Education, Counselling and Referral

Glaucoma is a chronic and inexorable disease with irreversible loss of visual function and requires unceasing commitment from patients to arrest further damage to their vision. Compliance to treatment and indefinite follow up on a regular basis is vital to success of therapy. It is not unusual for patients with advanced glaucoma to become depressed and despondent. The ophthalmologist should remain sensitive to these needs and provide support and encouragement. Understanding the disease in its proper perspective and implications of suboptimal or inadequate treatment (inevitable blindness) need to be conveyed to the patient by proper counselling. It has been proved that health education and counselling enhances patient compliance to treatment and contributes significantly to success of therapy. Patients with visual impairment and blindness should be referred and encouraged to use appropriate low vision aids and services. Referral to a subspecialist trained in glaucoma is suggested when any aspect of diagnosis or management of glaucoma is in question or if the disease is refractory to suggested measures of treatment.

Glaucoma Screening

Glaucoma blindness can only be prevented by early detection and appropriate treatment. Since POAG is largely asymptomatic, effective screening strategies are required for early diagnosis. Most glaucoma screening methods in the past were based on tonometry, which has only a sensitivity of 50-70% and a specificity of 10-30%¹². This indicates that a large number of individuals without the disease will need to undergo expensive and time consuming investigations, while a small number with definitive glaucoma will be presumed to be free of the disease. Most investigators believe that addition of another parameter for detection of glaucoma (optic disc evaluation and visual field analysis, targeting the high risk population for screening) will increase the sensitivity and specificity of the screening methods.

Tonometry

The efficiency of the screening methodology is vastly influenced by the type of tonometer employed. Schiottz tonometer is portable and IOP estimation is by a simple technique which can be delegated to trained para medical personnel. Schiottz tonometer, however reads significantly lower than the Goldmann applanation tonometer, which is the gold standard. The Perkins tonometer¹³ is a useful instrument for screening owing to its accuracy and portability, but is limited by its high cost and also the need for the skill and training required to operate it. The main problem with the use of IOP as a screening parameter is the overlap of its distribution in the glaucoma and non-glaucoma populations. Most population based studies have revealed that IOP distribution in the normal population is skewed to the right, and an IOP of 21 mmHg (two standard deviation from the mean in the normal population) is generally considered as a good cut-off IOP level for screening strategies. This concept is not without its disadvantages.

Optic disc evaluation

In a study on mass screening of glaucoma, Shiose¹⁴ et al had observed that based on IOP as a sole criterion to detect glaucoma, nearly half the individuals would be missed, while evaluation of optic disc alone would have overlooked a third of cases with glaucoma. Most studies seem to support the impression that optic disc evaluation is a more practical tool to detect glaucoma as compared to tonometry. However, due to ambiguity in interpretation of optic discs as also instances of high IOP in some eyes preceding nerve damage, it is recommended that both IOP estimation and optic disc evaluation¹⁵ be utilised to screen individuals for early detection of glaucoma.

Visual function tests

The main disadvantage of visual field analysis, which is the commonly employed psychophysical test in diagnosis of glaucoma as a mass screening tool is the fact that it is too time consuming and expensive. In a population based survey¹⁶, an automated suprathreshold testing with Humphrey's Field Analyser was completed in 89% of the sampled individuals and the median test time required was 7.25 minutes per eye. This method performed better than nonperimetric screening tools, though limited by logistic problems. Recently, introduction of the Frequency Doubling perimetry (FDT)⁴⁹ promises to be an efficient screening tool for early diagnosis of glaucoma. This technique evaluates the function of the M_y retinal ganglion cells which may be affected early in glaucoma. Recent studies in the west have established that this new perimetric technique is relatively cheap, and quick to perform when employed as a screening tool in glaucoma.

References

1. Hollows FC, Graham PA: *Intraocular pressure, glaucoma and glaucoma suspects in defined population*. *Br J Ophthalmol* 1966; 50:570-586.
2. Cartwright MJ, Anderson DR: *Correlation of asymmetric damage with asymmetric IOP in normal pressure glaucoma*. *Arch Ophthalmol* 1988; 106: 898-900.
3. Armaly MF: *On the distribution of applanation pressure and arcuate scotoma*. In: Paterson G, Miller SJH, Paterson GD, eds. *Drug Mechanisms in Glaucoma*. Boston, MA: Little Brown; 1966: 167-189.
4. Bengtsson B: *The prevalence of glaucoma*. *Br J Ophthalmol* 1981; 65: 46-49.
5. Palmberg P: *Etiology, epidemiology, management and therapy of primary open angle glaucoma*. In: *National Advisory Eye Council. Vision research; a national plan: 1983-1987. Report of the Glaucoma Panel, vol 2 part 4*. Bethesda, MD: US DHHS, PHS Publ(NIH) No 83-2475; 1983: 15-25.
6. Armaly MF, Kruger DE, Maunder LR, et al: *Biostatistical analysis of the collaborative Glaucoma study. I. Summary report of the risk factors for glaucomatous visual field defects*. *Arch Ophthalmol* 1980; 98:2163-2171.
7. Anderson DR: *The management of elevated IOP with normal optic disc and visual fields. I. Therapeutic approach based on high risk factors*. *Surv Ophthalmol* 1977; 21: 479-489.
8. Dandona L, Dandona R, Srinivas M, Mandal P, John RK, McCarty CA, Rao GN: *Open angle glaucoma in an urban population in Southern India: the Andhra Pradesh eye disease study*. *Ophthalmology* 2000; 107: 1702-1709.
9. Kaback MB, Burde RM, and Becker B: *Relative afferent pupillary defect in glaucoma*. *Am J Ophthalmol* 1976; 81: 462.
10. Armaly MF: *On the distribution of applanation pressure. I. Statistical features and effect of age, sex and family history of glaucoma*. *Arch Ophthalmol* 1965; 73:11.
11. Kitazawa Y, Shirato S, Yamamoto T: *Optic disc hemorrhage in low tension glaucoma*. *Ophthalmology* 1986; 93:853.

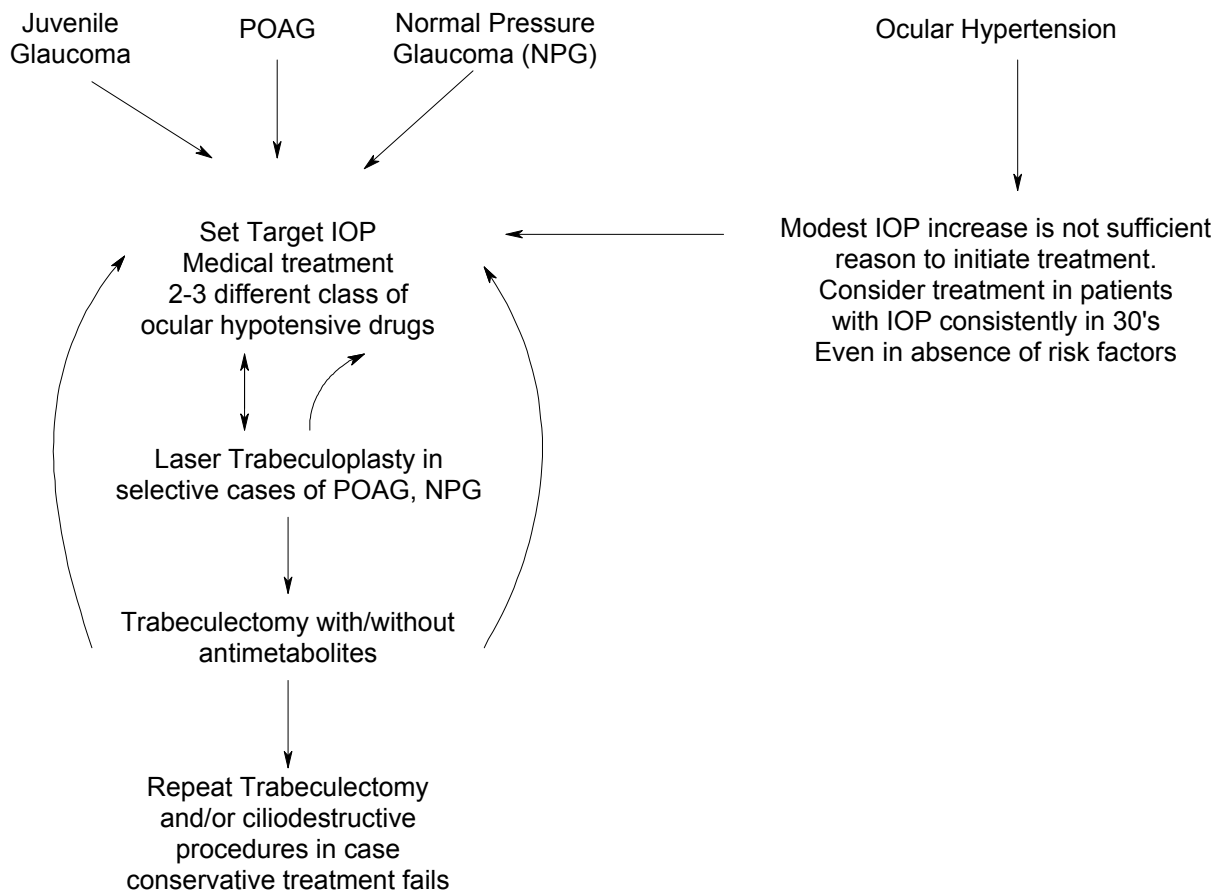
12. Kahn JA, Leibowitz HM, Ganley JP, et al: *The Framingham study, outline and major prevalence finding. Am J Epidemiology* 1977; 106:17.
 13. Kriegerstein GK, Waller WK: *Goldmann applanation versus hand held applanation and Schiotz indentation tonometry. Graefes Arch Clin Exp Ophthalmol* 1975; 194:11.
 14. Shiose Y, Komuro K, Itoh T, et al: *New system for mass screening of glaucoma, as part of automated multiphasic health testing services. Jpn J Ophthalmol* 1981; 25: 160.
 15. Bechetoille A, Aouchiche M, Hartani D: *The study of Touggart: a proposition for large scale discovery of glaucoma by examination of optic disc. J Fr Ophthalmol* 1980; 3:495.
 16. Katz J, Tielsch JM, Quigley HA, et al: *Automated suprathreshold screening for glaucoma: the Baltimore eye survey. Invest Ophthalmol Vis Sci* 1993; 34: 3271.
 17. Quigley HA, Miller NR, George T: *Clinical evaluation of nerve fiber layer atrophy as an indicator of glaucomatous optic nerve damage. Arch Ophthalmol* 1980; 98: 1564.
 18. Tuulonen A, Aireksinen PJ: *initial glaucomatous optic disc and retinal nerve fiber layer abnormalities and their progression. Am J Ophthalmol* 1991; 111: 485.
 19. Mao LK, Stewart WC, Shields MB : *Correlation between IOP and progressive glaucomatous damage in POAG. Am J Ophthalmol* 1991; 111: 51-55.
 20. Collaborative Normal-Tension Glaucoma Study Group: *Comparison of glaucomatous progression between untreated patients with normal-tension glaucoma and patients with therapeutically reduced intraocular pressure. Am J Ophthalmol* 1998; 126: 487-497.
 21. Odberg T: *Visual field prognosis in advanced glaucoma. Acta Ophthalmol* 65 (suppl) 1987; 182:27-29.
 22. Kolker AE: *Visual prognosis in advanced glaucoma. A comparison of medical and surgical therapy for retention of vision in 101 eyes with advanced glaucoma. Trans Am Ophthalmol soc* 1977; 75: 539-555.
 23. *Primary Open Angle Glaucoma. Preferred Practice Pattern. San Francisco: American Academy of Ophthalmology;1996.*
 24. Ashburn FS, Goldberg I, Kass MA: *Compliance with ocular therapy. Surv Ophthalmol* 1980; 24: 237-248.
 25. Lavin MJ, Wormald RP, Hitchings RA: *The influence of prior therapy on the success of trabeculectomy. Arch Ophthalmol* 1990; 108: 1543-1548.
 26. Shingleton BJ, Richter CU, Bellows AR, et al. *Long term efficacy of argon laser trabeculoplasty. Ophthalmology* 1987; 94: 1513-1518.
 27. Migdal C, Gregory W, Hitchings R: *Long term functional outcome after early surgery compared with laser and medicine and open angle glaucoma. Ophthalmology* 1994; 101: 1651-1656.
 28. Zimmerman TF, Kaufman HE: *Timolol: a beta adrenergic blocking agent for the treatment of glaucoma. Arch Ophthalmol* 1977; 95: 601-605.
 29. Watson PG: *Latanoprost: two years' experience of its use in the UK. Latanoprost study group. Ophthalmology* 1998; 105: 82-87.
 30. Katz LJ: *Brimonidine tartrate 0.2% vs timolol 0.5% twice daily: 1-year results in glaucoma patients. Brimonidine Study Group. Am J Ophthalmol* 1999; 127: 20-26.
 31. Adamsons IA, Polis A, Ostrov CS, Boyle JE: *2-year study of dorzolamide as monotherapy and with timolol and pilocarpine. Dorzolamide Safety Study Group. J Glaucoma* 1998; 7: 395-401.
-

32. *Glaucoma Laser Trial Research Group: The Glaucoma Laser Trial, 2: Results of argon laser trabeculoplasty versus topical medications. Ophthalmology 1990; 97: 1403-1407.*
 33. *Watson PG, Barnett F: Effectiveness of trabeculectomy in glaucoma. Am J Ophthalmol 1975; 79: 831-845.*
 34. *Wilson P: Trabeculectomy: Long term follow up. Br J Ophthalmol 1977; 61: 533-538.*
 35. *Watson PG, Grierson I: The place of trabeculectomy in the treatment of glaucoma. Ophthalmology 1981; 88: 175-196.*
 36. *D'Ermo F, Bonomi L, Doro D: A critical analysis of the long term results of trabeculectomy. Am J Ophthalmol 1979; 88: 829-835.*
 37. *Smith MF, Sherwood MB, Doyle JW, Khaw, PT: Results of intra operative 5 FU supplementation for trabeculectomy in open angle glaucoma. Am J Ophthalmol 1992; 114:737.*
 38. *Feldman RM, Dietz PJ, Gross RL, Oram O: Intraoperative 5 FU administration in trabeculectomy. J Glaucoma 1994; 3: 304.*
 39. *Robin AL, Ramakrishnan R, Krishnadas R, et al: A long term dose response study of mitomycin in glaucoma filtration surgery. Arch Ophthalmol 1997; 115:969-974.*
 40. *Kitazawa Y, Matsushita SH, Yuamomoto T, Kawase K: Low dose and high dose mitomycin trabeculectomy as an initial surgery in primary open angle glaucoma. Ophthalmology. 1993; 100: 1624-1628.*
 41. *Krupin TH, Juzych MS, Shin DH, et al: Adjunctive mitomycin C in primary trabeculectomy in phakic eyes. Am J Ophthalmol 1995; 119: 30-39.*
 42. *Ramakrishnan R, Michon J, Robin AL, Krishnadas R: Safety and efficacy of mitomycin C trabeculectomy in Southern India. Ophthalmology 1993; 100: 1619-1623.*
 43. *Hutchinson BT: Choroidal detachment and flat anterior chamber after filtering surgery in open angle glaucoma. In: Brockhurst RJ, Boruschoff SA, Hutchinson BT, Lessel S, eds. Controversy in ophthalmology. Philadelphia: WB Saunders CO; 1977: 248.*
 44. *Brubaker RF, Pederson JE: Ciliochoroidal detachment. Surv Ophthalmol 1983; 27:281-289.*
 45. *Gressel MG, Parrish RK, Heuer DK: Delayed nonexpulsive suprachoroidal haemorrhage. Arch Ophthalmol 1984; 102: 1757-1760.*
 46. *Lichter PR, Ravin JG: Risks of sudden visual loss after glaucoma surgery. Am J Ophthalmol 1974; 78: 1009-1013.*
 47. *Hattenhaeuer JM, Lipsich MP: Late endophthalmitis after filtering surgery. Am J Ophthalmol 1971; 72: 1097-1101.*
 48. *Sugar HS: post operative cataract in successfully filtering glaucomatous eye. Am J Ophthalmol 1970; 69:740-746.*
 49. *Quigley HA: Identification of glaucoma related visual field abnormality with the screening protocol of Frequency doubling technology. Am J Ophthalmol 1998; 125: 819-829.*
 50. *The Advanced Glaucoma Intervention Study (AGIS): 4. Comparison of treatment outcome within race. Ophthalmology 1998; 105: 1146-1164.*
-

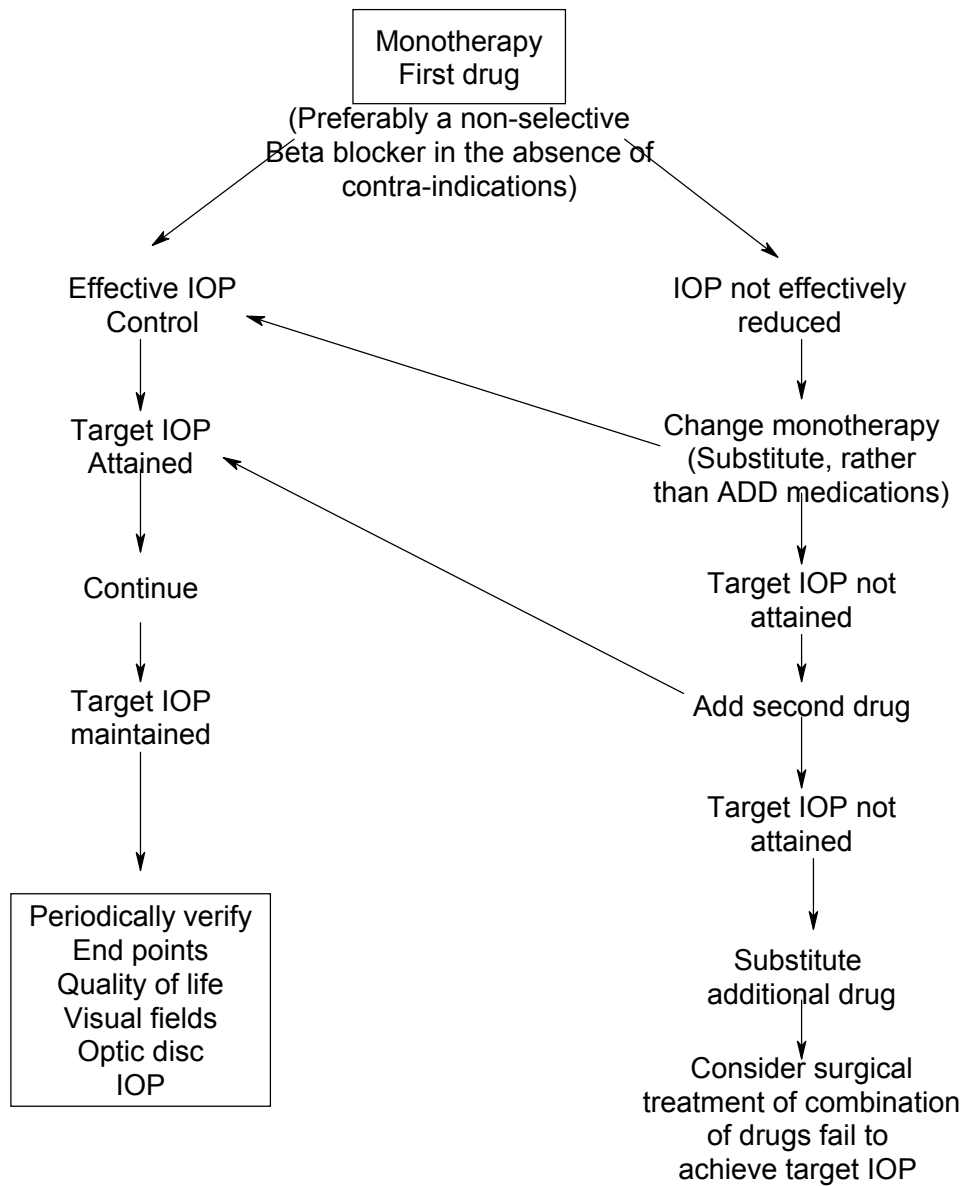
Appendix 1

Glaucoma Management (POAG)

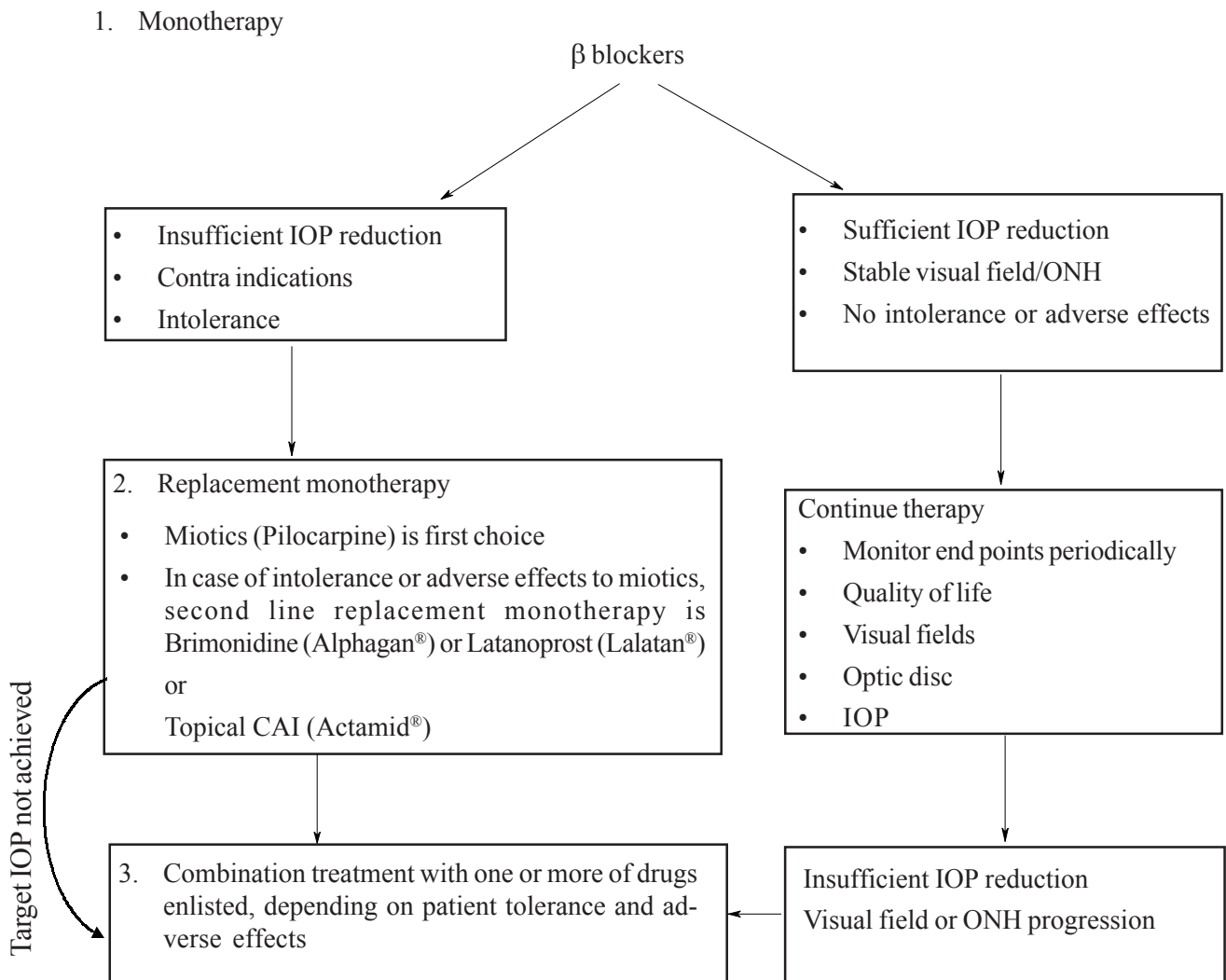
These are broad guidelines. Treatment to be tailored to individual variations depending on stage of disease, Rate of progression, Level of IOP, Response to treatment.



Therapeutic trial for glaucoma medications in management of POAG



POAG: Topical Medical Treatment



Modified from European Glaucoma Society Guidelines, 1998

