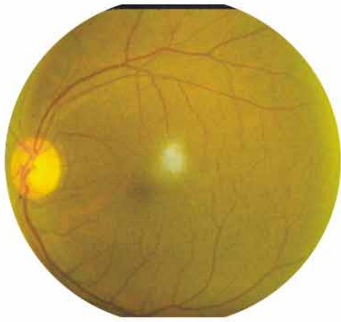
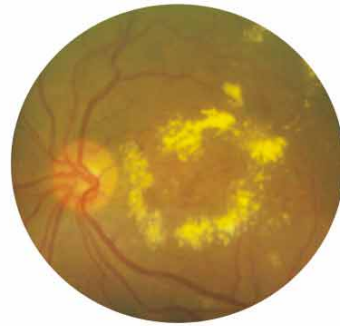

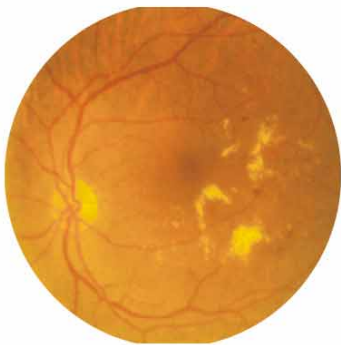
Stages of Diabetic Retinopathy



Normal Retina



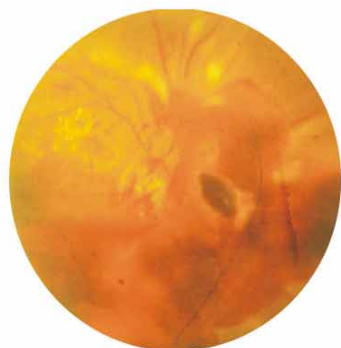Macular edema



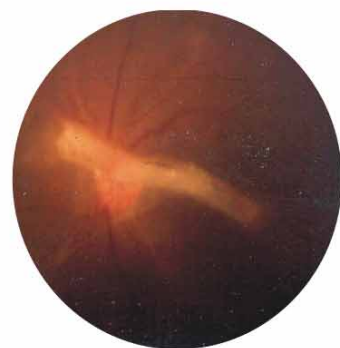
Background diabetic retinopathy
with minute bleeding



Proliferative diabetic
retinopathy (PDR)



PDR with bleeding



Tractional
retinal detachment